



Bursal Traumas: Epidemiological, Clinical and Therapeutic Aspects

Cyrille Ze Ondo^{1,*}, Amath Thiam¹, Alioune Sarr¹, Babacar Sine¹, Ndiaga Seck Ndour¹, Abdoulaye Ndiath¹, Ousmane Sow², Babacar Diao¹, Alain Khassim Ndoeye¹

¹Urology Department, University Hospital Center Aristide Le Dantec, Dakar, Senegal

²Urology Department, Regional Hospital, Linguere, Senegal

Email address:

zeczyrille28@gmail.com (Cyrille Ze Ondo), meta804@yahoo.fr (Amath Thiam), sarramoc@yahoo.fr (Alioune Sarr), papesine@yahoo.fr (Pape Sine), matarsn803@gmail.com (Ndiaga Seck Ndour), ndiath.ndiath23@gmail.com (Abdoulaye Ndiath), sowman87@gmail.com (Ousmane Sow), babacardiao104uro@yahoo.fr (Babacar Diao), alainndoye1964@gmail.com (Alain Khassim Ndoeye)

*Corresponding author

To cite this article:

Cyrille Ze Ondo, Amath Thiam, Alioune Sarr, Babacar Sine, Ndiaga Seck Ndour et al. (2023). Bursal Traumas: Epidemiological, Clinical and Therapeutic Aspects. *International Journal of Clinical Urology*, 7(2), 65-68. <https://doi.org/10.11648/j.ijcu.20230702.19>

Received: November 11, 2023, Accepted: November 28, 2023, Published: December 6, 2023

Abstract: *Introduction:* scrotal ou testicular trauma is often associated with low mortality with a significant risk of infertility in men. The aims of our study was to analyze the epidemiological, clinical and therapeutic aspects of bursal traumas. *Patients and methods:* retrospective descriptive study of 20 patients followed for bursal trauma from January 2007 to December 2021 at a university hospital in Senegal. Parameters studied: age, reason for consultation, consultation delay, nature of trauma, lesion assessment, treatment carried out and therapeutic results. The primary endpoint was the incidence of scrotal or testicular lesions. *Results:* The mean age of the patients was 32.7 years. Scrotal pain (n=19) was the most frequent reason for consultation. The average consultation time was 45 min. There was closed trauma in 14 patients and open trauma in 6. The main cause of closed trauma was road traffic accidents (n=9). Ultrasonography of the bursa was performed in all patients with closed bursal trauma, and hematocele (n=8) was the most frequent lesion revealed by this examination. Fifteen patients underwent surgery and 5 had conservative treatment. Evacuation of a hematocele (n=9) was the most frequently performed surgical procedure. Testicular lesions were the most common intraoperatively (n=10), with a predominance of AAST grade V lesions. Most of the post-operative course was straightforward. Three patients had oligoasthenozoospermia on the post-traumatic spermogram. *Conclusion:* bursal traumas was a rare emergency involving young adults. Few complications were noted after treatment.

Keywords: Bursa, Testicles, Trauma, Spermogram, Senegal

1. Introduction

Bursal traumas corresponds to injury to the bursal envelope or epididymo-testicular apparatus and/or spermatic cord as a result of physical aggression. These are rare emergencies which can jeopardize the functional prognosis of the testicle, with a significant risk of infertility [1, 2]. There are essentially 2 forms: opened and blunted traumas. The circumstances in which the latter occur are dominated by public road accidents, most often involving cars, motorcycles or bicycles [3].

The diagnosis of trauma is most often made on clinical examination by the presence of scrotal pain, ecchymosis or bursal oedema. In the case of blunted trauma, medical imaging exams may be required to assess the lesion [4, 5]. For a long time, Surgical exploration has for a long time been systematic as an emergency in the face of any bursal trauma. Complementary examinations have modified this attitude, with the introduction of watchful abstention in these cases [4, 6]. The aim of our work was to analyze the epidemiological, clinical and therapeutic aspects of bursal trauma in our department.

2. Materials and Methods

This was a retrospective descriptive study collating a series of 20 patients followed up for bursal trauma between January 1, 2007 and December 31, 2021 in a urology department of a university hospital center (CHU) in Senegal. The parameters studied were: patient age, reason for consultation, consultation time, nature of the trauma, lesion assessment, treatment carried out and therapeutic results. Testicular lesions were assessed according to the American Association of Trauma Surgeons (AAST) classification [7]. The primary endpoint was the incidence of scrotal or testicular lesions. The secondary endpoint was the occurrence of postoperative complications.

3. Results

The mean age of patients was 32.7 years, with extremes of 19 and 59 years. Scrotal pain (n=19) was the most frequent reason for consultation (figure 1). There was blunt trauma in 14 patients and opened trauma in 6. The main cause of closed trauma was road traffic accidents, including 4 falls from bicycles and 5 motorcycle accidents. Open traumas were mainly due to firearms (n=4) (Table 1). The average consultation time was 45 minutes, with extremes ranging from half an hour to 3600 hours. Bursal ultrasound was performed in all patients with blunt bursal trauma (n=14). Hematocele (n=8) was the most frequent lesion on ultrasound, and was associated with testicular fracture in 2 patients (figure 2). Fifteen patients underwent surgery and 5 were treated conservatively (monitoring with prescription of analgesics and/or non-steroidal anti-inflammatory drugs). Evacuation of a hematocele (n=9) was the most frequently performed surgical procedure (table 2). Patients with opened trauma to the bursa had all received antibiotic therapy and anti-tetanus serotherapy. Testicular lesions were the most common intraoperatively (n=10). According to the AAST classification, they were divided into grade V (n=5), grade IV (n=2), grade III (n=2) (figure 3) and grade I (n=1). Testicular avulsions were all observed in opened traumas (table 3). In 1 patient, ultrasound underestimated the lesions noted intraoperatively (scrotal hematoma when it was in fact a hematocele).

Average follow-up time was 9 months. Most of the post-operative course was uncomplicated. Two patients had testicular atrophy. Fourteen patients had a post-traumatic spermogram. Three patients had oligoasthenozoospermia. The spermogram was normal in cases of testicular avulsion.

Table 1. Distribution of patients by cause of trauma.

Trauma causes	Size
Blunt traumas	14
Public road accidents	9
Sports accidents (martial arts)	3
Marital dispute	1
Scaffolding fall	1
Opened traumas	6

Trauma causes	Size
Firearms	4
Fishing harpoon	1
Ox horn	1

Table 2. Distribution of patients according to treatment performed.

Gestures performed	Numbers
Hematocele evacuation + pulp resection + albuginea suture	6
Orchidectomy and scrotal reconstruction	4
Trimming and suturing of lesions	2
Isolated evacuation of hematocele	3
Watchful abstention	5

Table 3. Intraoperative lesions observed.

Intraoperative lesions	Numbers
Hematocele	6
Isolated scrotal hematoma	2
Scrotal hematoma + testicular contusion	1
Epididymal hematoma	1
Testicular fracture	2
Testicular fracture + hematocele	2
Testicular avulsion	5
Scrotal laceration	1

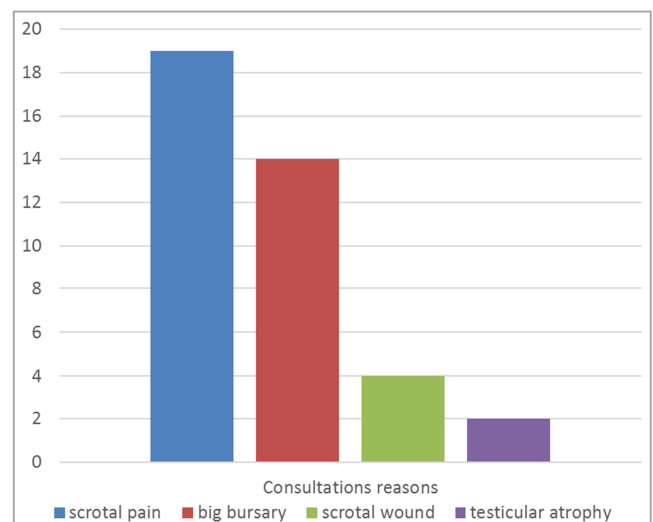


Figure 1. Consultations reasons.

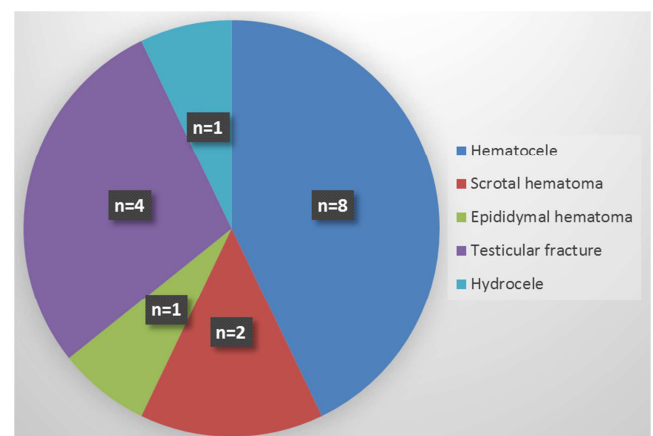


Figure 2. Ultrasound lesion distribution.

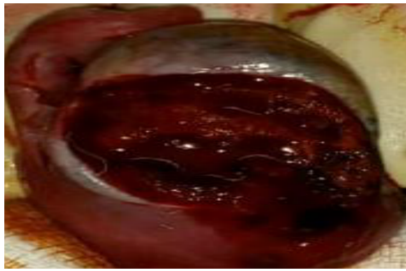

Figure 3. Grade III testicular fracture (AAST).

4. Discussion

We carried out a monocentric retrospective study of bursal trauma in one of our country's urology departments. Among the various activities carried out there, the management of urological emergencies occupied a primordial place. During the study period, we reported 20 cases of bursal trauma in 15 years. This type of emergency was rare in our department. This rarity has been reported in the literature by other authors [1, 8]. Indeed, scrotal trauma accounts for less than 1% of all trauma-related injuries, due to the anatomical location and mobility of the scrotum [1]. On the other hand, trauma to the bursal can go unnoticed, especially when it occurs in the context of polytrauma, where treating the life-threatening emergency is the top priority. On other occasions, especially when the scrotal pain is bearable, some patients are reluctant to come for consult, as they find it difficult to talk about their intimate organs for reasons of modesty.

The average age of our patients was 32.7, with extremes of 19 and 59. Young people were the most affected by bursal trauma [2, 9, 10]. One explanation for this phenomenon may be the high degree of exposure to bursal trauma in the young population, due to their various sporting activities (combat sports, soccer), professional activities (construction workers) or daily activities (use of two-wheeled means of locomotion with a tendency to speed).

In our series, 14 patients had blunt traumas and 6 patients had opened traumas. In general, there are 2 situations to consider when assessing scrotal trauma: either a blunt injury or a penetrating wound [11]. Blunt injuries are described as the vast majority (75-80%) of genital trauma [12]. However, an analysis of the National Trauma Data Bank in the USA described a more balanced distribution of penetrating and blunt trauma to the scrotum, with both accounting for almost half of all injuries [2]. This significant difference in reported mechanism may be attributable to geopolitical determinants, for example there is an increased incidence of gunshot wounds in the USA compared to other countries [13].

We used scrotal ultrasound in all our patients with closed bursal trauma. This examination provides important information in this context, as it is often difficult to properly examine a traumatic bursa due to the intensity of the pain. Scrotal ultrasound plays an important role in the precise diagnosis of traumatic lesions. It can demonstrate a testicular fracture with 100% sensitivity and 65% specificity, a

hematocele with 87% sensitivity and 89% specificity, or testicular avulsion with 100% sensitivity and 97% specificity [14].

The use of Doppler in bursal trauma is reserved for situations in which conventional examination has been non-contributory. Doppler provides information on the integrity of testicular vascularization, and confirms testicular fracture when there is a break in the continuity of a hypoechoic testicular albuginea [4, 15]. Moreover, the existence of vascularization in the testicular parenchyma indicates the latter's capacity for functional recovery after the trauma [4]. The use of magnetic resonance imaging (MRI) in bursal trauma is not at all conventional, as it is not an easily obtainable examination and its cost remains high. However, MRI may be necessary in the presence of an intra-testicular hematoma in a situation of unrecognized bursal trauma, to rule out a hemorrhage related to testicular cancer [5, 16].

In the case of bursal trauma, the use of additional examinations can help guide therapeutic indications. Indeed, surgical exploration was the systematic therapeutic approach adopted for all types of bursal trauma. Thanks to advances in medical imaging, watchful abstention has also become a valid therapeutic option, particularly in the case of closed bursal trauma. This abstention most often requires the use of analgesics, bursal suspension and regular ultrasound monitoring [4, 17].

The majority of our patients underwent surgical exploration (n=15), which systematically involved all open bursal injuries. Indeed, these lesions require urgent surgical exploration with excision of any non-viable tissue, and particular attention must be paid to the neighbor structures like spermatic cord, the vas deferens and its blood vessels [12]. Most open traumas were secondary to firearms in our patients (n=4). The principles of management of gunshot wounds additionally include irrigation of the tissues involved, extraction of foreign bodies and antibiotic prophylaxis [12, 18]. In addition, exploration of the contralateral testicle should be systematic in these conditions, as 30% of gunshot wounds are accompanied by bilateral testicular trauma [18].

The delay in therapeutic management of bursal trauma appears to have an influence on testicular prognosis. Indeed, early intervention would result in over 90% testicular preservation, while late intervention would result in an orchiectomy rate of 45-55% [4, 19]. Nevertheless, we noted 4 orchiectomies in our series, despite a short average consultation time.

Testicular function is significantly affected by trauma of any kind to the bursal, with a particular risk of male infertility. There are several possible explanations for this risk, such as rupture of the blood-testicular barrier due to ischemic disorders, testicular atrophy that may last several months, damage to the epididymis or vas deferens, or even orchiectomy [1, 4]. We noted post-traumatic testicular atrophy in 2 patients. Among the 14 patients who had a spermogram, we noted disturbances of this examination in 3 patients.

Our work had limitations that may alter the analysis of our results. In this respect, the biases we identified were the small size of our population, the fact that our study was retrospective and carried out in a single center, and the insufficient 9-month follow-up. To compensate to these limitations, we recommend carrying out a prospective national multicenter study with a view to having a larger sample size and obtaining information from all over our country, and a sufficiently long follow-up would enable a more accurate assessment of the impact of bursal trauma on male exocrine function.

5. Conclusion

Bursal Traumas were rare emergencies, and more often involved young adults. Closed trauma was the most frequent. The majority of patients underwent emergency surgical exploration. Evacuation of the hematocele was the most common therapeutic procedure. Few complications were noted during the follow-up period.

Conflicts of Interest

The authors declare no conflicts of interest.

References

- [1] Deurduian C, Mittelstaedt CA, Chong WK, et al. US of acute scrotal trauma: Optimal technique, imaging findings, and management. *Radiographics* 2007, 27: 357-69. DOI: 10.1148/rg.272065117.
- [2] Grigorian A, Livingston JK, Schubl SD, Hasjim BJ, Mayers D, Kuncir E et al. National analysis of testicular and scrotal trauma in the USA. *Research and Reports in Urology* 2018: 10 51–56. DOI: 10.2147/RRU.S172848. eCollection 2018.
- [3] Paparel P, N'Diaye A, Laumon B, Caillot JL, Perrin P, Ruffion A. The epidemiology of trauma of the genitourinary system after traffic accidents: analysis of a register of over 43,000 victims. *BJU Int* 2006, 97 (2): 338-341. DOI: 10.1111/j.1464-410X.2006.05900.x.
- [4] Robledo XG, Gualdrón YG, Vallecilla KV, Díaz-Hung A, García-Perdomo HA. Testicular Doppler ultrasound in scrotal trauma: A diagnostic tool with potentially relevant therapeutic implications. *Can Urol Assoc J* 2021, 15 (7): 366-369. DOI: 10.5489/cuaj.6840.
- [5] Tsili AC, Argyropoulou MI, Dolcianni M, Ercolani G, Catalano C, Manganaro L. When to ask for an MRI of the scrotum. *Andrology* 2021, 9: 1395–1409. DOI: 10.1111/andr.13032. Epub 2021 Jun 11.
- [6] Morey AF, Brandes S, David D, et al. Urotrauma: AUA guideline. *J Urol* 2014, 192: 1-9. DOI: 10.1016/j.juro.2014.05.004.
- [7] Mohr AM, Pham AM, Lavery RF et al. Management of trauma to the male external genitalia: the usefulness of American Association for the Surgery of Trauma organ injury scales. *J Urol* 2003, 170: 2311. doi: 10.1097/01.ju.0000089241.71369.f.
- [8] Gross M. Rupture of the testicle: the importance of early surgical treatment. *J Urol*. 1969, 101 (2): 196–197. DOI: 10.1016/s0022-5347(17)62310-3.
- [9] Barthélémy Y, Delmas V, Villers A, Baron JC, Sibert A, Boccon Gibod L. Traumatisme des bourses. A propos de 33 cas. [Scrotal trauma. Report of 33 cases]. *Prog. Urol.* 1992 Aug-Sept, 2 (4): 628634.
- [10] Lynch TH, Martínez-Piñeiro L, Plas E, et al. EAU guidelines on urological trauma. *Eur Urol* 2005, 47: 1-15. DOI: 10.1016/j.eururo.2004.07.028.
- [11] Morey AF, Metro MJ, Carney KJ, Miller KS, McAninch JW. Consensus on genitourinary trauma: external genitalia. *BJU Int* 2004, 94 (4): 507–515. DOI: 10.1111/j.1464-410X.2004.04993.x.
- [12] Kitrey ND, Campos-Juanatey F, Hallscheidt P, Mayer E, E. Serafetinidis E, D. M. Sharma DM et al. EAU guidelines on urological trauma. *European Association of Urology*, 2023. Available at: <https://uroweb.org/individual-guidelines/non-oncology-guidelines/>. Accessed 6 October 2023.
- [13] Rees CA, Monuteaux MC, Steidley I, Mannix R, Lee LK, Barrett JT, Flegler EW. Trends and Disparities in Firearm Fatalities in the United States, 1990-2021. *JAMA Netw Open* 2022, 5 (11): e2244221. DOI: 10.1001/jamanetworkopen.2022.44221.
- [14] Guichard G, El Ammari J, Del Coro C, et al. Accuracy of ultrasonography in diagnosis of testicular rupture after blunt scrotal trauma. *Imag Clin Urol* 2008, 71: 52-6. DOI: 10.1016/j.urology.2007.09.014.
- [15] Schnobrich DJ, Gilbert BR. Scrotum, testes, and paratesticular structures. *Springer Nat* 2018, 165-72. DOI: 10.1007/978-3-319-73855-0_32.
- [16] Tsili AC, Bertolotto M, Rocher L, et al. Sonographically indeterminate scrotal masses: how MRI helps in characterization. *Diagn Interv Radiol.* 2018, 24: 225- 236. DOI: 10.5152/dir.2018.17400.
- [17] Coffin G, Méria P, Desgrandchamps F. [Traumatismos de los órganos genitales externos]. *EMC Urol* 2013, 45: 1-12. DOI.org/10.1016/S1761-3310(13)64161-4.
- [18] Mc Geady JB, Breyer BN. Current epidemiology of genitourinary trauma. *Urologic Clin North Am* 2013, 40: 323–334. DOI: 10.1016/j.ucl.2013.04.001.
- [19] Cass AS, Luxenberg M. Testicular injuries. *Urology* 1991, XXXVII: 528-30. DOI: 10.1016/0090-4295(91)80317-z.