



Case Report

Late Diagnosis of Ovotesticular Disorders of Sexual Development: A Case Report and Literature Review

Pare Abdoul-Karim^{1,*}, Ouattara Adama¹, Ye Delphine¹, Kabre Boukary²,
Abubakar Babagana Mustapha³, Simpure Mohamed¹, Rouamba Mickael¹,
Kabore Aristide Fasnewinde⁴, Kambou Timothee¹

¹Department of Urology, Sourou Sanou University Teaching Hospital, Bobo-Dioulasso, Burkina Faso

²Department of Surgery, Regional Hospital of Tenkodogo, Tenkodogo, Burkina Faso

³Department of Surgery, Federal Medical Center Nguru, Yobe, Nigeria

⁴Department of Urology, Yalgado Ouedraogo University Teaching Hospital, Ouagadougou, Burkina Faso

Email address:

boupare@yahoo.fr (Pare Abdoul-Karim)

*Corresponding author

To cite this article:

Pare Abdoul-Karim., Ouattara Adama, Ye Delphine, Kabre Boukary, Abubakar Babagana Mustapha, Simpure Mohamed, Rouamba Mickael, Kabore Aristide Fasnewinde, Kambou Timothee. Late Diagnosis of Ovotesticular Disorders of Sexual Development: A Case Report and Literature Review. *International Journal of Clinical Urology*. Vol. 7, No. 2, 2023, pp. 61-64. doi: 10.11648/j.ijcu.20230702.18

Received: October 18, 2023; **Accepted:** November 3, 2023; **Published:** November 11, 2023

Abstract: Background: Disorders of sex development (DSD) are a group of congenital conditions associated with anomalous development of internal and external genital organs. Ovotesticular disorders of sexual development formerly called true hermaphroditism are the rarest of all types of disorders of sexual development. It refers to individuals who have both ovarian and testicular tissues in the same or contralateral gonad, regardless of their karyotype. Case presentation: Ovotesticular DSDs are usually diagnosed in the pediatric age group. We reported a rare case of ovotesticular DSD in an adult, originally assigned as male gender. He was referred to our service with the complaint of difficulty with sexual intercourse and genital ambiguity. On examination, he was found to have gynecomastia, a female pelvic, a left testicle, micropenis, and proximal hypospadias. A total abdominal hysterectomy with penile reconstruction and left orchidopexy was performed. Hypospadias repair was planned to be done later. We aim to highlight the challenges urologists practising in a poor-resource community face in diagnosing and managing of these cases. Conclusions: Ovotesticular DSD is rare. Diagnosis is usually made clinically supported by laboratory, imaging and histological evaluation. Treatment consists of multidisciplinary management including urologists, gynaecologists, endocrinologists, paediatricians, and psychiatrists. It is important to involve the patient and their family in shared decision-making before surgery or gender assignment.

Keywords: Ovotesticular, Disorders of Sexual Development, Hypospadias, Karyotype

1. Introduction

Ovotesticular disorders of sexual development (DSD) refer to individuals who have both ovarian and testicular tissues in the same or contralateral gonad, regardless of their karyotype [1]. Typically, both Mullerian and Wolffian duct derivatives are present and the external genitalia is ambiguous. The patient's phenotype dictates the sex of rearing and this typically depends on which gonad is the dominant one [2]. It is

one of the rarest sex development disorders. Indeed, Ovotesticular DSD represents less than, 10% of all DSD which occur in 1 in 4500 births [3]. We reported a rare case of ovotesticular DSD in an adult, originally assigned as male. We aim to highlight the challenges that can be faced in the diagnosis and management of these cases by urologists practising in a poor-resource community.

2. Case Presentation

A 32-year-old male, originally assigned and reared as a boy, presented at the urology unit with the complaint of difficulty with sexual intercourse and genital ambiguity discovered by his sexual partner. He admits having noticed a difference in his external genitalia with other boys since childhood but never sought medical assistance. There was no history of parental consanguinity or potential prenatal exposure to androgens, androgen antagonists or other drugs. He has morning erections and normal libido. He had periodic and intermittent menstruation since puberty which was normal according to the patient. He has a feminine voice. On examination, he was found to have gynecomastia (Figure 1), a female pelvic, a left testicle, micropenis, and proximal hypospadias (Figure 2). The abdominal ultrasound shows a uterus and a left ovary. The hormonal investigation, as well as the karyotype, were not available. Psychiatry consultation revealed an adjustment disorder with normal mood without psychosocial development disorder. Counselling about gender assignments was given. The male sex was freely chosen by the patient. A diagnostic open abdominal and pelvic surgery was offered to the patient. The exploration confirms the presence of a uterus which continues with the fallopian tubes on both sides, and a left ovary. The left testicle was not found in scrotum (Figure 3). A total abdominal hysterectomy with penile reconstruction and left orchidopexy was performed (Figures 4 and 5). The post-operative period was uneventful. The histology of the specimens revealed a fallopian tube, a uterus and ovarian tissues. Hypospadias repair was planned to be done as a staged procedure.

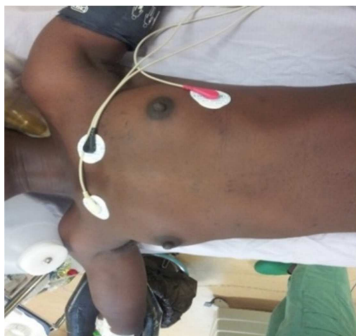


Figure 1. Bilateral gynecomastia.

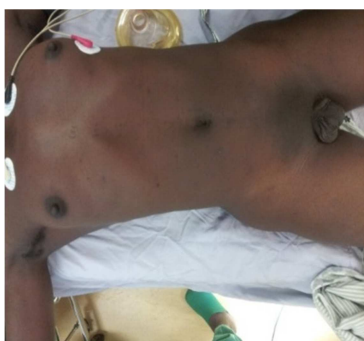

Figure 2. Female pelvic and empty left scrotum.

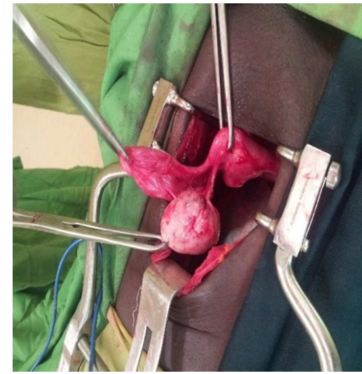


Figure 3. Uterus, tube and left ovary.

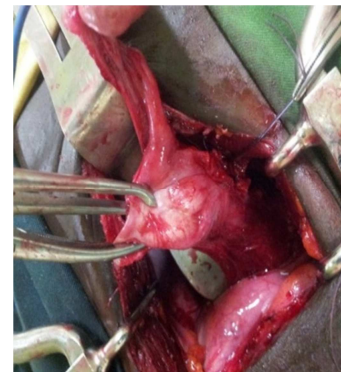


Figure 4. Started total hysterectomy.

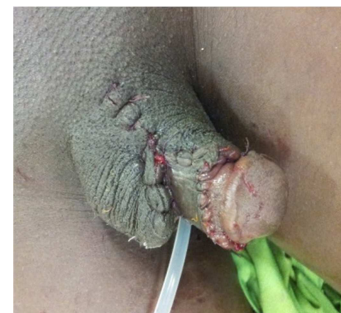


Figure 5. Right orchidopexy and penile elongation and glanduloplasty.

3. Discussion

DSD is the consensus term used to name intersex and sexual ambiguity. In the same idea, ovotesticular DSD has replaced the formerly called true hermaphrodite, recognizing the fact that the disorder can only be defined by the knowledge of gonadal histology by the presence of ovarian follicles, testicular tissue or both [4]. These new terminologies followed the international consensus back in 2005, recognising the fact that the former term was considered discriminatory and did not respect human rights as well [5]. Then, DSD refers to congenital conditions within which the development of chromosomal, gonadal and anatomic sex is atypical. While ovotesticular DSD means the presence of ovarian and testicular tissue in the same individual, meaning that both female and male structures are present in the same individual [6].

DSD is rare and occurs in 1/4500 births. Ovotesticular DSD

is the rarest disorder of sex development in humans and has an approximate incidence of less than 1/20,000. At least 500 affected individuals have been reported [7].

In Ovotesticular DSD, the external genitalia ranged from phenotypically nearly female to normal male. Regarding the karyotype, it may be 46, XX; or 46, XY the first one being the most frequent [8]. About the gonads, ovotestes are the most frequently found followed by ovaries and testis. Ovaries are more frequently seen on the left side and are usually functioning. Testes can be seen anywhere along the line of descent, but are generally non-functioning due to poor germ-cell development from high estrogen levels [9].

Less than 20% are diagnosed by 5 years of age and 75% are diagnosed by 20 years. Ovarian development occurs in the absence of the Y-linked SRY gene and results in a female phenotype [10]. Because the presence of a Y chromosome is a risk factor for neoplasia in patients with gonadal dysgenesis, the 46, XX/SRY-negative karyotype in our patient might be advantageous [11]. In our patient, the ovary was on the left side and the testicle was on the right side.

Ovaries appear normal and demonstrate follicular growth with estradiol production. Indeed, nearly one-half of ovotestes patients show evidence of ovulation. The presence of estradiol in developing ovarian follicles usually inhibits spermatogonia development in adjacent or contralateral seminiferous tubules [12]. Our patient had irregular menstruation but the semen analysis was not checked.

Most patients with ovotesticular DSD present with ambiguous genitalia at the time of birth. These patients are at risk of developing gonadal tumours. Indeed, the incidence of gonadal tumours in ovotesticular DSD has been estimated to be 2.6% [13]. Our patient was admitted with micropenis in adulthood.

Gender assignment is done based on the functional potential of genitalia and gonads and the gender identity of the patient. Early and appropriate gender assignment is necessary for the proper physical and psychological development of the patient with ambiguous genitalia [14]. Unfortunately, in our case, the patient had even finished high school without seeking any medical attention until his first sexual partner requested him to do so. Gender assignment requires a multidisciplinary team approach that involves endocrinologists, geneticists, urologists, psychiatrists, social workers, nurses, radiologists, and paediatricians, allowing timely diagnosis and proper management.

Hypospadias and undescended testes may suggest a disorder of sexual differentiation and the guidelines recommend that clinicians should suspect the possibility of a DSD in patients with both hypospadias and cryptorchidism [15]. In our case, hypospadias was present and the left testis was absent in scrotum suggesting left cryptorchidism.

4. Conclusion

Ovotesticular DSD is a rare case. Only a few cases have been found and documented. Karyotype, as well as hormonal evaluation and histology, play a key role in the diagnosis.

Treatment consists of multidisciplinary management including urologists, gynaecologists, endocrinologists, paediatricians, and psychiatrists.

Conflicts of Interest

The authors declare that there are no conflicts of interest regarding the publication of this article.

Ethical Approval

Written consent was obtained from the patient for publication of this case report and any accompanying images. Ethical approval was obtained from the local *ethical committee*.

Authors' Contributions

Pare AK participated to the surgical management of the patient and contributed to the data collection, analysis of case and the drafting of the manuscript.

Ouattara A participated to the surgical management of the patient and contributed to evaluation and revised the manuscript.

Ye D participated to the surgical management

Kabre B contributed to analysis of case and the drafting of the manuscript

Abubakar BM revised the manuscript

Simpore M participated to the surgical management

Rouamba M participated to the surgical management

Kabore AF revised the manuscript.

Kambou T contributed to the surgical management of the case

All of the authors have read and approved the final manuscript.

References

- [1] Hughes IA. Disorders of sex development: a new definition and classification. *Best Pract Res Clin Endocrinol Metab.* 2008; 22: 119-34.
- [2] MacLaughlin, D. T., Donahoe, P. K. Sex determination and differentiation. *N. Engl. J. Med.* 2004; 350: 367-78.
- [3] Eiji Hisamatsu Nakagawa Y, and Sugita Y. Two Cases of Late-Diagnosed Ovotesticular Disorder of Sex Development. *APSP J Case Rep.* 2013; 4 (3): 40.
- [4] Houk CP, Hughes LA, Ahmed SF, Peter A Lee PA, et al. Summary of Consensus Statement on Intersex Disorders and Their Management. *International Intersex Consensus Conference. Paediatrics.* 2006; 118 (2): 753-7.
- [5] Parliamentary Assembly, Council of Europe. Promoting the human rights of and eliminating discrimination against intersex people. 2017.
- [6] Jyothi GA, Waghay N. A case report on ovotesticular DSD. *Apollo Medicine.* 2016; 13 (1): 49-51.

- [7] DaryantoB, NaimHY. A case report: 46, XX ovotesticular DSD. *The Pan African Medical Journal*. 2018; 31 (Supp 1): 10.
- [8] Dutta D, Shivaprasad KS, Das RN, Ghosh S, Chatterjee U, Chowdhury S et al. Ovotesticular disorder of sexual development due to 47, XYY/46, XY/45, X mixed gonadal dysgenesis in a phenotypic male presenting as cyclical haematuria: clinical presentation and assessment of long-term outcomes. *Andrologia*. 2014; 46 (2): 191-3.
- [9] Sircili MH, Denes FT, Costa EM, Machado MG, Inacio M, Silva RB, et al. Long-term follow-up of a large cohort of patients with ovotesticular disorder of sex development. *J Urol*. 2014; 191 (5 Suppl): 1532-6.
- [10] Kilberg MJ, McLoughlin M, Pyle LC, Vogiatzi MG. Endocrine Management of Ovotesticular DSD, an Index Case and Review of the Literature. *Pediatr Endocrinol Rev*. 2019; 17 (2), 110-116.
- [11] Matsui F, Shimada K, Matsumoto F, Itesako T, Nara K, Ida S, Nakayama M. Long-term outcome of ovotesticular disorder of sex development: a single centre experience. *Int J Urol*. 2011; 18: 231-236.
- [12] Wolffenbuttel, KP, Hersmus R, Stoop H, Biermann K, Hoebeke P, Cools M, et al. Gonadal dysgenesis in disorders of sex development: Diagnosis and surgical management. *J Pediatr Urol*; 2016. 12: 411.
- [13] Cox MJ, Coplen DE, Austin PF. The incidence of disorders of sexual differentiation and chromosomal abnormalities of cryptorchidism and hypospadias stratified by meatal location. *J Urol*. 2008; 180: 2649–52.
- [14] Mouriquand PDE, Brindusa Gorduza D, Gay CL, Meyer-Bahlburg HFL, Baskin LS, et al. Surgery in disorders of sex development (DSD) with a gender issue: if (why); when, and how? *J Pediatr Urol*. 2016; 12: 139-49.
- [15] Guerrero-Fernández J, San Julián CA, Barreiro Conde J, Bermúdez de la Vega JA, Carcavilla Urquí A, Castaño González LA, et al. Management guidelines for disorders/different sex development (DSD). *A Pediatr (Barc)*. 2018; 89 (5). e1-315. e19.