

Place of Scrotal Doppler Ultrasound in the Diagnosis of Male Infertility in Conakry, Guinea

Diallo Thierno Mamadou Oury^{1,*}, Diallo Thierno Oumar¹, Bah Mamadou Diawo¹, Bah Kadiatou², Diallo Alimou¹, Bah Mamadou Bissirieu¹, Kanté Daouda¹, Gnammi Lahoumbo Ricardo¹, Diallo Alpha Oumar¹, Diallo Abdoulaye Bobo¹, Bah Oumar Raphiou¹

¹Urology-Andrology Department, Ignace Deen National Hospital in Conakry, Faculty of Health Sciences and Techniques of Conakry, Conakry, Guinea

²Exploration and Diagnostic Medical Imaging Practice in Conakry, Conakry, Guinea

Email address:

oury_uro@yahoo.fr (Diallo Thierno Mamadou Oury), thiernobgl87@gmail.com (Diallo Thierno Oumar), oumarbobo1975@gmail.com (Bah Mamadou Diawo), drbahmamadou@yahoo.fr (Bah Mamadou Bissirieu), daoudak68@gmail.com (Kanté Daouda), alimouurologie@gmail.com (Diallo Alimou), rickhardo84@gmail.com (Gnammi Lahoumbo Ricardo), docaodd87@gmail.com (Diallo Alpha Oumar), abobodiallo@gmail.com (Diallo Abdoulaye Bobo), raphiouuro.orb@gmail.com (Bah Oumar Raphiou)

*Corresponding author

To cite this article:

Diallo Thierno Mamadou Oury, Diallo Thierno Oumar, Bah Mamadou Diawo, Bah Kadiatou, Diallo Alimou, Bah Mamadou Bissirieu, Kanté Daouda, Gnammi Lahoumbo Ricardo, Diallo Alpha Oumar, Diallo Abdoulaye Bobo, Bah Oumar Raphiou. Place of Scrotal Doppler Ultrasound in the Diagnosis of Male Infertility in Conakry, Guinea. *International Journal of Clinical Urology*. Vol. 7, No. 2, 2023, pp. 57-60. doi: 10.11648/j.ijcu.20230702.17

Received: August 28, 2023; **Accepted:** September 14, 2023; **Published:** September 27, 2023

Abstract: Introduction: The imaging assessment of the male genital tract in the diagnostic evaluation of infertile men is based on scrotal Doppler ultrasound. The objective of this study was to determine the place of scrotal ultrasound in the diagnosis of male infertility. Methodology: This was a descriptive retrospective study lasting 3 years, from January 1st, 2019 to December 31, 2021. It focused on patients referred to the medical imaging, exploration and diagnosis in Conakry for a scrotal ultrasound in the context of couple infertility. Results: 241 patients were seen for scrotal ultrasound for infertility. An ultrasound abnormality was found in 181 patients (75.1%). The average age of the patients was 41.5 years with extremes of 26 and 67 years. The localization of abnormalities identified on ultrasound was predominant in the spermatic cord with 127 cases (70.2%), followed by testicular, epididymal and scrotal affections. There was an association of abnormalities in 40.9% of cases (n=74). Varicocele was the main ultrasound anomaly of the spermatic cord, 66.8% (121 cases) followed by testicular hypotrophy and epididymal cysts. Conclusion: Scrotal ultrasound occupies an important place in the diagnostic process of male infertility.

Keywords: Male Infertility, Doppler Ultrasound, Scrotum, Varicocele

1. Introduction

According to the WHO, about 15% of couples are affected by infertility worldwide with about 50% of male etiologies mentioned [1]. In Guinea in 2007, male infertility occupied 8.2% of consultations in the urology department of the Ignace Deen National Hospital [2].

The diagnostic evaluation of the infertile man must include a clinical examination, a spermological assessment and

imaging of the uro-genital sphere. The imaging assessment of the male genital tract is based on scrotal Doppler ultrasound. It is an accessible, non-invasive and easy-to-perform examination [3]. It is recommended by the French Association of Urology and the French-speaking Andrology Society in addition to the clinical examination, mainly to screen for non-palpable tumors [4]. However, in practice, it makes it possible to evaluate potential testicular abnormalities, to identify abnormalities of the epididymis and

vas and to grade a possible varicocele [5, 6].

The objective of this study was to report the place of scrotal ultrasound in the diagnosis of male infertility at the Conakry Medical Exploration and Diagnostic Imaging Cabinet.

2. Material and Methods

This was a retrospective study lasting 3 years from January 2019 to December 31, 2021. It focused on patients referred by urologists to the medical imaging, exploration and diagnosis practice in Conakry for a scrotal ultrasound in the context of marital infertility.

We included in this study, patients with couple infertility for more than 12 months, and having performed at least one spermogram showing sperm abnormalities and a scrotal ultrasound.

All ultrasounds were performed by the same experienced operator using a Technos Partner ultrasound scanner equipped with a 12.5 MHz high-frequency probe and coupled to Doppler.

The volume of the testis was calculated by Lampert's formula: $L \times E \times l \times 0.7$. A testicular volume less than 9 ml was considered as hypotrophic and a volume less than or equal to 5 ml as atrophic.

Varicocele was retained in the presence of scrotal veins with a diameter greater than 3 mm in the supine position and the existence on Doppler of continuous or intermittent spontaneous reflux or on the Valsalva maneuver. Grading was done according to the Hirsh classification.

Data were collected using a questionnaire on patient characteristics and scrotal Doppler ultrasound results.

Data analysis was performed using SPSS version 25 software. A descriptive analysis was performed taking into account the type of variable. Quantitative data were described by the mean and standard deviation for those that follow a normal distribution and by the median where appropriate. The qualitative variables were described with the proportions.

3. Results

During the study period, 3284 ultrasounds were performed, 241 of which were for an infertility assessment, i.e. 7.34%. An ultrasound abnormality was found in 181 patients (75.1%), of whom 69 (38.1%) presented with azoospermia and 112 (61.9%) with oligoasthenoteratozoospermia.

The average age of the patients was 41.5 years with extremes of 26 and 67 years.

The localization of the abnormalities identified on ultrasound was predominant at the level of the spermatic cord with 127 cases (70.2%), followed by testicular, epididymal and scrotal affections (figure 1). There was an association of abnormalities in 40.9% of cases ($n=74$).

Varicocele (figure 2) was the main ultrasound anomaly of the spermatic cord with 66.8% (121 cases), followed by cord cyst with 3.3% (6 cases). The varicocele was bilateral in 60.3

($n=73$), left unilateral in 35.5% ($n=43$) and right unilateral in 4.13% ($n=5$). Grade 2 varicocele was the most common with 85 cases (70.3%) followed by grade 3 varicocele with 32 cases (26.5%).

At the testicular level, volume anomalies including testicular hypotrophy with 38 cases and testicular atrophy with 4 cases were the most frequent; followed by testicular microlithiasis (figure 3) with 15 cases. A case of testicular seminoma was found. Other testicular abnormalities are shown in Table 1.

Epididymal cysts (figure 4) were the predominant lesion with 41 cases (22.6%) among epididymal abnormalities, followed by chronic epididymitis in 5 cases.

All scrotal abnormalities diagnosed on ultrasound were hydroceles ($n=21$).

Table 1. Distribution of patients according to testicular abnormalities.

Testicular abnormalities	Effective (N=181)	Percentage (%)
Testicular hypotrophy	38	20.9
Testicular microcalcifications	15	8.3
Testicular atrophy	9	4.9
Chronic orchitis	8	4.4
Cryptorchidism	3	1.7
Testicular seminoma	1	0.6
Anorchidia	1	0.6

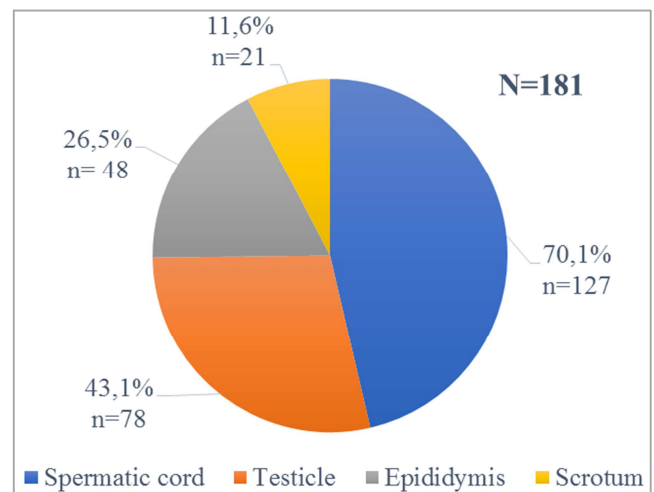
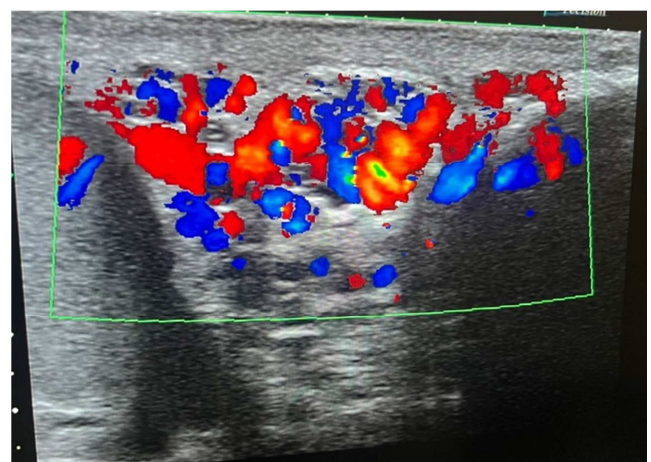


Figure 1. Location of abnormalities identified on ultrasound.



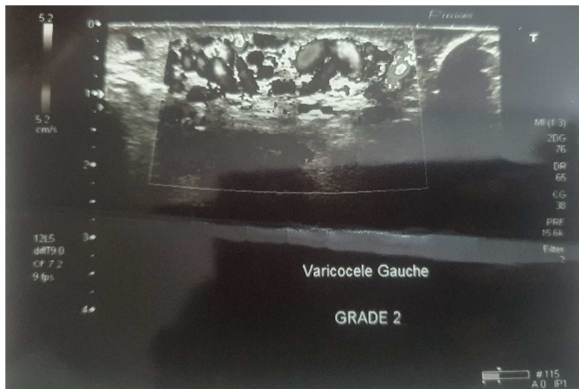


Figure 2. Varicoceles with dilated veins and venous reflux.

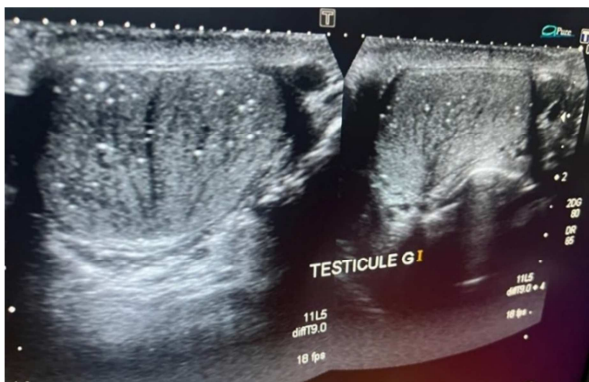

Figure 3. Multiple testicular microlithiasis.

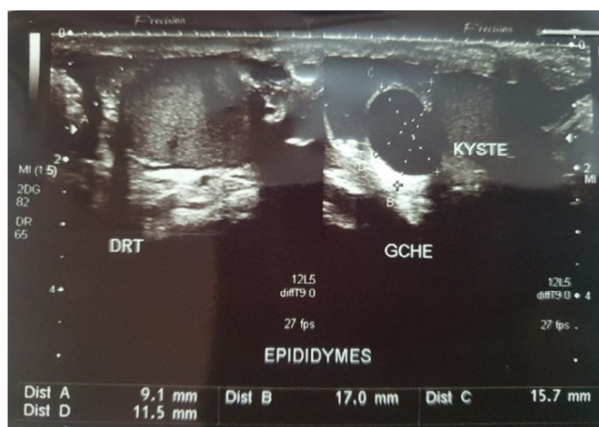


Figure 4. Left epididymal cysts.

4. Discussion

The causes of male infertility are varied and often multifactorial [7]. Scrotal ultrasound should in no way replace clinical examination. However, it is recommended for all infertile men because of the diagnostic, prognostic and etiological information it provides, as well as the close link between male infertility and testicular cancer [4].

We studied the results of scrotal Doppler ultrasound in the exploration of the infertile man. An ultrasound abnormality was present in 181 patients, or 75.1%, out of 241 patients who performed an ultrasound for male infertility.

The average age in our study is higher than most of the average ages found in series of patients consulting for

infertility [8, 9]. This advanced age at the consultation is explained by the fact that men, often confusing virility and fertility, do not consult until late.

Varicocele remains the most found anomaly in this series. It is present in 15% of the general male population. Its prevalence is estimated at around 35-40% in primary infertility and 75-81% in secondary infertility [10, 11]. There is no indication to perform subclinical varicocele screening by scrotal Doppler. Only clinical varicoceles should be treated in the context of infertility [4].

On the other hand, the scrotal venous Doppler makes it possible to complete the assessment of a clinical varicocele (size, duration of reflux in the Valsalva maneuver) and can help to confirm the presence of a varicocele when the physical examination is equivocal (retraction of the scrotum, associated vaginal hydrocele) [4].

We noted a predominance of bilateral forms with more than 60% of cases. This corroborates the data of several studies [12] stating that varicocele is a bilateral disease. On the other hand, Diallo [13] and Gueye [14] objectified a predominance of unilateral left varicocele with more than 80% of cases.

The scrotal ultrasound assessment is important to assess the size of the testicles, due to the subjectivity of the scrotal clinical examination [4]. Testicular hypotrophy, which was the most frequently found ultrasound anomaly in the testis, may go unnoticed during the clinical examination in certain anxious patients who present with retraction of the scrotum with ascent of the testicles at the level of the inguinal ring. It was associated with a varicocele in 27 patients. The decrease in testicular volume in the infertile subject is correlated with the decrease in the number of spermatozoa and the loss of testicular function [15]. Testicular hypotrophy was the most frequent anomaly with 36.3% in the study by Goullet et al [16].

The incidence of intra testicular microcalcifications is between 0.05% and 0.6% depending on the series [17, 18]. In our study, they were mentioned in 15 patients. These microcalcifications, although rare, must be given special attention. Beyond 20 microcalcifications, annual ultrasound monitoring is necessary, due to the possible association with a seminoma [19].

Tumor pathology is more common in infertile patients, due to associations or history of cryptorchidism or microlithiasis. The morphological study of the two testicles must therefore be very careful, looking for an intratesticular tumor which is malignant in more than 80% of testicular tumors diagnosed [19]. We recorded a case of testicular seminoma.

The usual criteria of malignancy on ultrasound are a hypoechoic and heterogeneous appearance with irregular contours and anarchic vascularization on color Doppler very different from the usual intratesticular radial vascularization [19].

The attentive and fine exploration of the epididymis makes it possible to detect obstructive, inflammatory or tumoral epididymo-deferential pathologies. Cysts were the most frequent lesion of the epididymis. They are considered

benign in most cases, as they are not associated with impaired sperm quality [4]. Only large cysts may require decompression surgery according to Granier JL [19]. Indeed, large epididymal cysts can lead to obstruction of the spermatic pathway [16]. An increase in the volume of the epididymal head is often associated with obstructive azoospermia [20]. The inflammatory pathology is quite often located at the level of the epididymo-deferential junction with a hypoechoic and poorly vascularized aspect on Doppler [19].

Our study has some limitations related to its retrospective nature. Also in this descriptive study, we have only reported the conclusions of the scrotal Doppler ultrasound performed in infertile patients referred to the practice for exploration. Other prospective and analytical studies could complete this first study to assess the sensitivity and specificity of scrotal Doppler ultrasound and correlate ultrasound abnormalities with seminal and hormonal parameters.

5. Conclusion

Scrotal Doppler ultrasound is an accessible, non-invasive but operator-dependent examination. Our study highlights the important place it occupies in the diagnostic assessment of the infertile man. It confirms clinically perceived lesions, or reveals subclinical lesions of the scrotum, testis, epididymis and spermatic cord. Varicocele and testicular volume abnormalities were the main lesions found in this study. This work must be completed by others to analyze the sensitivity and specificity of the examination.

References

- [1] Katz DJ, Teloken P, Shoshany O. (2017). Male infertility - The other side of the equation. *Aust Fam Physician*, 46: 641-646.
- [2] Bah OR, Diallo AB, Diallo A, Guirassy S, Bah I, Diallo MB. (2007). Male infertility: frequency and etiological aspects in the Urology-Andrology department of the University Hospital of Conakry. *Andrology*, 17: 241-5.
- [3] Brunerau L. (2015). Imaging of male infertility. *EMC Urologie*, 10 (2): 1-15 [34-510-A-10]. [https://doi.org/10.1016/S1241-8218\(06\)43071-7](https://doi.org/10.1016/S1241-8218(06)43071-7).
- [4] Huyghe E, Boitrelle F, Methorst C, Mieusset R, Ray PF, Akakpo W, and al. (2021). Recommendations of the AFU and the SALF concerning the evaluation of the infertile man. *Progrès en Urologie*, 3: 131-144. <https://doi.org/10.1016/j.purol.2020.09.011>
- [5] Mittal PK, Little B, Harri PA, Miller FH, Alexander LF, Kalb B, Camacho JC, Master V, Hartman M, Moreno CC. (2017). Role of imaging in the evaluation of male infertility. *Radiographics*, 37: 837-854. <https://doi.org/10.1148/rg.2017160125>
- [6] Rocher L, Balasa C, Hindawi G, Bresson B, Maxwell F. (2020). Ultrasound in male infertility screening. *Journal d'imagerie diagnostique et interventionnelle*, 3: 12-17. <https://doi.org/10.1016/j.jidi.2019.11.004>
- [7] Schlossera J, Nakib I, Carré-Pigeon F, Staermana F. (2007) Male infertility: definition and pathophysiology. *Annales d'urologie*, 41: 127-133. <https://doi.org/10.1016/j.anuro.2007.02.004>
- [8] Fall B, Diao YS, Sarr P., Fall A., Ndoeye MB. (2010). Impact of varicocelelectomy in patients with non-obstructive azoospermia or severe oligozoospermia. *Andrology*, 20: 257-61.
- [9] Kirakoya B, Zango B, Pare A, Kabore F, Yameogo C, Nikiema A. (2015). Epidemiological and clinical profile of male hypofertility in consultation at the Urology-Andrology of Yalgadogo Ouedraogo Teaching Hospital (Burkina Faso). *Advances in Sexual Medicine*, 5: 1-6. <http://dx.doi.org/10.4236/asm.2015.51001>
- [10] Alsaikhan B, Alrabeeah K, Delouya G, Zini A. (2016). Epidemiology of varicocele. *Asian Journal of Andrology*, 18: 179-181. <https://doi.org/10.4103/1008-682X.172640>
- [11] Freeman S, Bertolotto M, Richenberg J, Belfield J, Dogra V, Huang DY, and al. (2020). Ultrasound evaluation of varicoceles: guidelines and recommendations of the European Society of Urogenital Radiology Scrotal and Penile Imaging Working Group. *European Radiology*, 30: 11-25. <https://doi.org/10.1007/s00330-019-06280-y>.
- [12] Gat Y, Bachar GN, Zukerman Z, Belenky A, Gornish M. (2004). Varicocele: a bilateral disease. *Journal of Urology*, 172: 790-1. <https://doi.org/10.1016/j.jfertnstert.2003.08.010>.
- [13] Diallo AB, Bah I, Barry M, Diallo TMO, Bah MD, Kanté D, and al. (2015). Adult varicocele: anatomo-clinical aspects and therapeutic results in the urology-andrology department of the University Hospital of Conakry, Guinea. *African Journal of Urology*, 21: 137-41. <https://doi.org/10.1016/j.afju.2015.02.002>
- [14] Gueye SM, Fall P, Ndoeye A, Ba M, Daffé A, Afoutou J, and al. (1999). Influence of surgical treatment of varicocele on sperm quality. *Andrology*, 9: 376-9.
- [15] Lotti F, Maggi M. (2015). Ultrasound of the male genital tract in relation to male reproductive health. *Human Reproduction Update*, 21: 56-83. <https://doi.org/10.1093/humupd/dmu042>
- [16] Gouillet E, Rigot J, Blois N. (2000). Interest of systematic scrotal ultrasound in the management of infertile men: prospective study of 609 cases in Lille. *Progrès en Urologie*, 10: 78-82.
- [17] Hobarth K, Susani M, Szabo N, Kratzik C. (1992). Incidence of testicular microlithiasis. *Urology*, 40: 464-7. [https://doi.org/10.1016/0090-4295\(92\)90467-b](https://doi.org/10.1016/0090-4295(92)90467-b)
- [18] Kessaris D, Mellinger B. (1994). Incidence and implication of testicular microlithiasis detected by scrotal duplex sonography in a select group of infertile men. *J Urol*, 152: 1560-1. [https://doi.org/10.1016/s0022-5347\(17\)32472-2](https://doi.org/10.1016/s0022-5347(17)32472-2).
- [19] Granier JL. (2009). Contribution of ultrasound in the assessment of male infertility. *Andrology*, 19: 159-67.
- [20] Pezzella A, Barbonetti A, Micillo A, D'Andrea S, Necozone S, Gandini L, and al. (2013). Ultrasonographic determination of caput epididymis diameter is strongly predictive of obstruction in the genital tract in azoospermic men with normal serum FSH. *Andrology*, 1: 133-8.