

Nephrectomy in the Management of Emphysematous Pyelonephritis: Analysis of a Case and Review of the Literature

Bah Mamadou Bissiriu^{1,2,*}, Barry Mamadou Madiou¹, Barry Mamadou Dian¹,
Diallo Thierno Oumar¹, Sow Thierno Amadou Oury¹, Frederic Arroua², Marc Fourmarier²,
Christophe Eghazarian²

¹Urology Department, Ignace Deen Hospital, Conakry, Guinea

²Urology Department, Centre Hospital Aix-Pertuis, Aix, France

Email address:

drbahmamadou@yahoo.fr (Bah Mamadou Bissiriu)

*Corresponding author

To cite this article:

Bah Mamadou Bissiriu, Barry Mamadou Madiou, Barry Mamadou Dian, Diallo Thierno Oumar, Sow Thierno Amadou Oury, Frederic Arroua, Marc Fourmarier, Christophe Eghazarian. Nephrectomy in the Management of Emphysematous Pyelonephritis: Analysis of a Case and Review of the Literature. *International Journal of Clinical Urology*. Vol. 7, No. 2, 2023, pp. 53-56. doi: 10.11648/j.ijcu.20230702.16

Received: July 15, 2023; **Accepted:** September 8, 2023; **Published:** September 27, 2023

Abstract: *Introduction:* Emphysematous pyelonephritis is a rare and serious medical-surgical condition. Emergency nephrectomy is the standard treatment for forms that respond poorly to medical therapy, in conjunction with drainage of the upper excretory tract. *Case report:* This is a case of emphysematous pyelonephritis in a 54-year-old female patient who had presented with acute pyelonephritis, left renal colic and hyperactivity syndrome. A non-injected abdominopelvic CT scan revealed a globular, dedifferentiated left kidney with a diffuse aortic component. The right kidney was unremarkable. In intensive care, despite placement of a double JJ tube and antibiotic therapy with amikacin and cefotaxime, the patient's hemodynamic and neurological status continued to deteriorate, necessitating intubation. After 24 hours of well-managed treatment with no improvement, nephrectomy was performed in the setting of emphysematous destruction of the left kidney and persistent latent shock. Based on this observation and a review of the literature, we describe the clinical and radiological features, as well as the various diagnostic and therapeutic means of this condition. *Conclusion:* the diagnosis of emphysematous pyelonephritis should be suspected in the following cases: the presence of severe acute pyelonephritis, with no improvement in clinical condition despite well-conducted medical treatment or percutaneous drainage, or associated with signs of severity, particularly in diabetics, radical treatment is envisaged after failure of drug therapy.

Keywords: Nephrectomy, Emphysematus Pyelonephritis, Diabetic, Hospital National Ignace Deen, Emergency

1. Introduction

Emphysematous pyelonephritis (EPP) is a renal suppuration that generally occurs in diabetic or immunocompromised patients, with a predominance of women and an average age of 57 [1]. A rapid and serious medical-surgical emergency, it is often life-threatening due to septic shock and multiple visceral failures. Without prompt treatment, emphysematous pyelonephritis is often fatal [1, 2]. Most authors recommend nephrectomy as a matter of principle, but conservative treatment may be

indicated in special cases [3]. We report an unfavorable case of PNE after medical treatment and drainage of the upper part of the excretory tract cavities in a diabetic patient.

The aim of this article was to highlight the histological, clinical and radiological features, as well as the various diagnostic and therapeutic means of this condition.

2. Observation

This was a 54-year-old female patient, diabetic for 10 years, referred by her attending physician to the emergency

department for glycemic imbalance on acute left pyelonephritis. On arrival, the patient was clinically stable, but the laboratory work-up revealed acute renal failure, with creatinine level at 321 mmol/L, hyponatremia at 115 mmol/L, blood glucose at 40 mmol/L and a biological inflammatory syndrome with CRP at 400 mmol/L. Cytobacteriological examination of the urine showed a urinary tract infection with *Escherichia coli*. A non-injected abdominopelvic CT scan (Figure 1) revealed a globular, dedifferentiated left kidney with a diffuse aeric component (potentially related to acute parenchymal pyelonephritis) and dilatation of the pyelocalic cavities (Stage 2 of Huang and Tseng's radiological classification) (Table 1). This stage of emphysematous pyelonephritis did not indicate radical surgical management, but medical treatment combining antibiotic therapy, insulin therapy and drainage of the upper excretory tract.

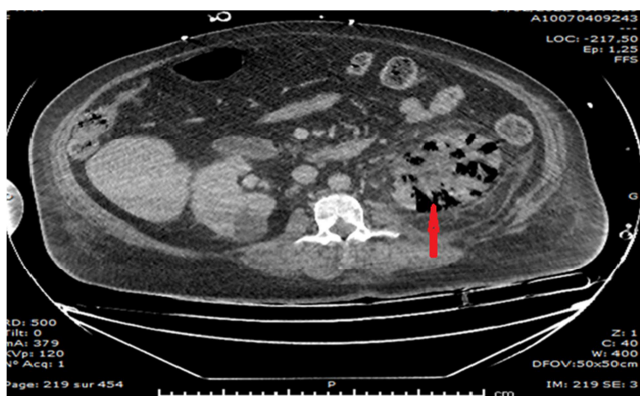


Figure 1. CT scan of multiple emphysematous ANP of the left kidney.

Table 1. CT scan revealed gas in the right kidney (class 2) indicated by a red arrow. Table 1: CT scan revealed gas in the right kidney (class 2) indicated by a red arrow.

Stage	Description
Stage 1	Gas in excretory tract only
Stage 2	gas in the renal parenchyma without extension into the extra-renal space
Stage 3A:	extension of gas or abscess into the perinephric space
Stage 3B:	gas extension or abscess in the paranephric space
Stage 4:	bilateral or single kidney ENP

After renal drainage and initiation of antibiotic therapy with Cefotaxime and Amikacin. The patient was transferred to intensive care. The patient's hemodynamic and neurological status deteriorated, necessitating intubation. Noradrenaline and hydrocortisone were administered, and Cefotaxime was replaced by Tazocillin. After 48 hours with no improvement, nephrectomy was performed for an emphysematous tumor, destruction of the left kidney and persistence of induced shock. The surgical specimen (Figure 2) was sent to the pathologist, who concluded that the patient was suffering from type II emphysematous pyelonephritis (Wan et al), characterized macroscopically by diffuse infiltration, inflammatory cells (leukocytes) and exudate, abscess formation and necrosis.

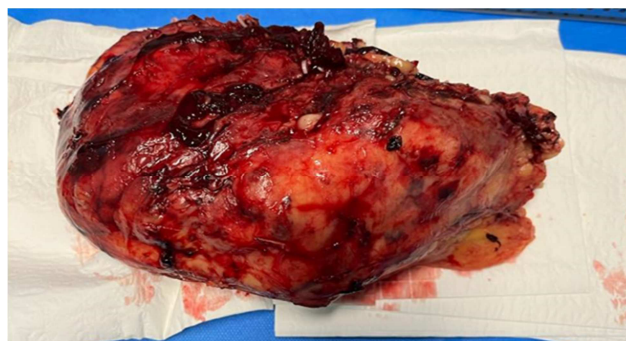

Figure 2. Surgical specimen of an emphysematous NAP of the G. nothing.

The post-operative course was straightforward. After resuscitation, antibiotic therapy with Tazocillin for 8 days and insulin therapy, the patient was transferred to nephrology for management of her renal failure.

3. Discussion

First described in 1898 by Kelly and Mc Callum and reported by Sarf [4], the term emphysematous pyelonephritis was first used by Schultz and Klorfeinin in 1962 to describe this serious infection. Mortality varies from 7 to 75% depending on the series [5] in diabetic patients in Asia and industrialized countries [6]. Its diagnosis should be suspected in the presence of pyelonephritis that responds poorly to treatment or is associated with signs of severity, particularly in diabetics [7]. Bilateral involvement is rare and serious, and mortality is 20 times more lethal. In the literature, unilateral involvement is the most common, with the left side affected in around 60% of cases, as in our patient [2]. Two etiological factors are frequently identified. The first is diabetes, a fortiori poorly controlled. The second is the existence of urinary tract obstruction (20 to 41% of cases) [8, 9], the latter factor being rarely observed in diabetics. In contrast, lithiasis is the usual etiology in non-diabetics [10, 11]. The occurrence of severe forms in diabetics is due to chronic hyperglycemia, which favors microangiopathy, anatomical and functional abnormalities of the urinary tract, and abnormalities of antibacterial immunity. Diabetic neuropathy also delays diagnosis by reducing pain symptomatology [12]. The occurrence of severe forms in diabetics is due to chronic hyperglycemia, which favors microangiopathy, anatomical and functional abnormalities of the urinary tract, and abnormalities of antibacterial immunity. Diabetic neuropathy also delays diagnosis by reducing pain symptomatology. It should be noted that the pathophysiology of EPN is still debated, with the hypotheses of intra-renal fermentation of glucose, the presence of microbes and a tissue environment conducive to infection [10]. Thus, these three conditions are necessary for the development of EPN [9].

The presence of gas-producing bacteria, high tissue sugar levels and renal blood hypoperfusion. The germ most often found is *E. Coli* or *Klebsiella pneumoniae* in 65% to 100% of cases, according to several authors; other germs are rarely incriminated [10 13]. In our patient, *Escherichia coli* was the

germ isolated on cytobacteriological examination of urine, confirming the frequency of this germ in ENP. There were no specific clinical signs of this medico-surgical pathology, which generally manifests itself as severe acute pyelonephritis [14]. The features that should attract attention are the abruptness of the symptoms, occurring in a diabetic patient with a recent deterioration in general condition possibly associated with signs of cardiovascular collapse [12]. Signs of sepsis are often associated. Lumbar pain is found in only 50% of cases, and palpation of crepitation in the homolateral lumbar fossa is suggestive but rarely found [15]. PNE-induced sepsis is confirmed by biology. Hyper-creatininemia, hyper-uremia, consumptive coagulopathy, metabolic acidosis, pulmonary and hepatic damage, all indicate sepsis-induced multivisceral failure [12, 15]. The presence of gas-producing bacteria, high tissue sugar levels and renal blood hypoperfusion. The germ most often found is *E. Coli* or *Klebsiella pneumoniae* in 65% to 100% of cases, according to several authors; other germs are rarely incriminated [10, 13]. In our patient, *Escherichia coli* was the germ isolated on cytobacteriological examination of urine, confirming the frequency of this germ in ENP. There were no specific clinical signs of this medico-surgical pathology, which generally manifests itself as severe acute pyelonephritis [14]. The features that should attract attention are the abruptness of the symptoms, occurring in a diabetic patient with a recent deterioration in general condition, possibly associated with signs of cardiovascular collapse [12]. Signs of sepsis are often associated. Lumbar pain is found in only 50% of cases, and palpation of crepitation in the homolateral lumbar fossa is suggestive but rarely found [15]. PNE-induced sepsis is confirmed by biology. Hyper-creatininemia, hyper-uremia, consumptive coagulopathy, metabolic acidosis, pulmonary and hepatic damage, all point to sepsis-induced multivisceral failure [12, 15]. Positive diagnosis of ENP relies on CT scans. Its sensitivity is estimated at 100% for detecting gases in the renal parenchyma and assessing its quality. It can also be used to study the perirenal spaces and thus determine the extent of lesions. It helps to establish a classification with prognostic value to guide indications for therapeutic decisions concerning conservative or radical treatment [16]. In our observation, CT scan without injection enabled the diagnosis to be made. In all cases, contrast injection is not mandatory to establish the diagnosis [17]. Treatment of ENP remains controversial: until the mid-1980s, the standard treatment was nephrectomy of the affected kidney [18]. Several authors [3] now recommend three treatment modalities: pure medical treatment, medical treatment combined with percutaneous drainage, and nephrectomy. In our patient, nephrectomy was indicated in view of the instability of her hemodynamic parameters due to sepsis, despite effective drainage and well-administered antibiotic therapy. In all cases, the choice of treatment depends on the stability of hemodynamic parameters, radiological classification and the existence or absence of signs of sepsis. For the management of this condition, Huang [19] has

defined 4 major radiological classes of ENP, with corresponding therapeutic indications. For localized ENP (classes 1 and 2), percutaneous drainage and/or removal of obstruction combined with medical treatment offers good results. For extensive ENP (class 3 and 4) with benign manifestations (less than two risk factors), percutaneous drainage combined with medical treatment would be the 1st-line treatment. For extensive ENP with fulminant progression (two or more risk factors), nephrectomy provides the best results and should be performed rapidly.

4. Conclusion

ENP is a rare condition with serious repercussions on vital functions. It is most frequently diagnosed in diabetic patients, and relies heavily on CT scans. Treatment must be urgent and early. Nephrectomy still has a place in the management of severe forms resistant to medical treatment, combined with drainage of the excretory tract.

References

- [1] Abdelouahed Lasri1, Amine Saouli, Othmane Yddoussalah Emphysematous pyelonephritis with favorable evolution after medical treatment: about 3 observations Pan African Medical Journal. 2018; 30: 223.
- [2] E. Kaiser, R. Fournier Emphysematous pyelonephritis: diagnosis and treatment Annales d'urologie 39 (2005) 49-60.
- [3] Driss TOUITI, Emmanuel DELIGNE, Lionel BADET, Marc COLOMBEL, Xavier MARTIN, Albert GELET La pyélonéphrite emphysémateuse: à propos de 3 observations Progrès en Urologie (2001), 11, 703-706.
- [4] Sarf I, Meziane A, Dahami Z, Dakir M, Jaoual A, Bennani S, et al. Emphysematous pyelonephritis: review of the literature concerning a case report. Ann Urol 2003; 37: 54-6.
- [5] WanYL, Lo SK, Bullard MJ, Chang PL, Lee TY. Predictors of outcome in emphysematous pyelonephritis. J Urol 1998; 159: 369-73.
- [6] Grimaldi A. Diabète de type 2: l'épidémie annoncée est en cours. Rev Prat. 2003; 53 (10): 1067-8.
- [7] R. Kapoor, K. Muruganandham, A. K. Gulia, M. Singla, S. Agrawal, A. Mandhani, A. Srivastava, Predictive factors for mortality and need for nephrectomy in patients with emphysematous pyelonephritis, BJU Int. 105 (7) (2010) 986-989.
- [8] Miane D, Beatrix O, Bregion M, Sabbah P, Altobelli A, Boyer C. Pyélonéphrite emphysémateuse. Complication rare du diabète sucré. Med Armees. 1996; 24: 583-6.
- [9] K. Aswathaman, G. Gopalakrishnan, L. Gnanaraj, N. K. Chacko, N. S. Kekre, A. Devasia, Emphysematous pyelonephritis: outcome of conservative management, Urology 71 (6) (2008) 1007-1009.
- [10] Emphysematous cystitis: illustrative case report and review of the literature. Grupper M, Kravtsov A, Potasman I. Medicine (Baltimore) 2007; 86: 47-53.

- [11] Hudson MA, Weyman PJ, Van Der Vliet AH, Catalona WJ. Emphysematous pyelonephritis: Successful management by percutaneous drainage. *J Urol.* 1986; 136 (4): 884-885. Article 11 et 14.
- [12] P. Dutta, A. Bhansali, S. K. Singh, K. L. Gupta, M. H. Bhat, S. R. Masoodi, Y. Kumar, Presentation and outcome of emphysematous renal tract disease in patients with diabetes mellitus, *Urol. Int.* 78 (1) (2007) 13-22.
- [13] Pyélonéphrite emphysemateuse fulminante à *Candida glabrata* dans une allogreffe de rein. Cases-Corona C, Shabaka A, Gonzalez-Lopez A, Martin-Segarra O, Moreno de la Higuera MA, Lucena R, Fernandez-Juarez G. *Nephron.* 2020; 144: 304-309.
- [14] Moez Rahoui *, Yassine Ouane, Kays Chaker, Mokhtar Bibi Predictive factors for failure of conservative management in patients with emphysematous pyelonephritis *Annals of Medicine and Surgery* 78 (2022) 103930.
- [15] M. E. Falagas, V. G. Alexiou, K. P. Giannopoulou, Siempos II, Risk factors for mortality in patients with emphysematous pyelonephritis: a meta-analysis, *J. Urol.* 178 (2007) 880-885.
- [16] Aswathaman, G. Gopalakrishnan, L. Gnanaraj, N. K. Chacko, N. S. Kekre, A. Devasia, Emphysematous pyelonephritis: outcome of conservative management, *Urology* 71 (6) (2008) 1007-1009.
- [17] Shokeir AA, El-Azab M, Mohsen T, El-Diasty T. Emphysematous pyelonephritis: a 15-year experience with 20 cases. *Urology* 1997; 49: 343-6. 15.
- [18] Hooton T. Urinary tract infection in adults. In: JurgeonF, Johnson RJ, Feehally J, editors. *Comprehensive Clinical Nephrology*. 4th ed. Philadelphia: Mosby, Elsevier Inc; 2010. p. 638-9.
- [19] Huang JJ, Tseng CC. Emphysematous pyelonephritis: Clinicoradiological classification, management, prognosis and pathogenesis. *Arch Intern Med.* 2000; 160 (6): 797-805.