



Contribution of Histopathology to the Diagnosis of Buschke-Löwenstein Tumour in a Cameroonian Child and Suspected Child Abuse

Coralie Reine Bertine Mendouga Menye^{1, 2, 3, *}, Emmanuel Armand Kouotou¹, Jean Cedrick Fouda¹, Rene Ghislain Essomba^{1, 3}, Frantz Guy Epoupa Ngalle¹, Paul Jean Adrien Atangana^{2, 4}

¹Faculty of Medicine and Biomedical Sciences, The University of Yaoundé I, Yaounde, Cameroon

²Anatomy and Cytopathology Unit, «Centre Pasteur of Cameroon», Yaounde, Cameroon

³Anatomy and Pathology Division, National Public Health Laboratory, Yaounde, Cameroon

⁴Faculty of Medicine and Pharmaceutical Sciences, University of Douala, Douala, Cameroon

Email address:

coraliereine86@gmail.com (Coralie Reine Bertine Mendouga Menye)

*Corresponding author

To cite this article:

Coralie Reine Bertine Mendouga Menye, Emmanuel Armand Kouotou, Jean Cedrick Fouda, Rene Ghislain Essomba, Frantz Guy Epoupa Ngalle, Paul Jean Adrien Atangana. Contribution of Histopathology to the Diagnosis of Buschke-Löwenstein Tumour in a Cameroonian Child and Suspected Child Abuse. *International Journal of Clinical Urology*. Vol. 6, No. 2, 2022, pp. 122-125.

doi: 10.11648/j.ijcu.20220602.19

Received: November 11, 2022; Accepted: December 2, 2022; Published: December 27, 2022

Abstract: *Introduction:* Buschke-Löwenstein tumour (BLT) is a rare sexually transmitted infection of the skin caused by the Human Papilloma Virus with common involvement of the types 6 and 11. The preferential location being the genital area. It is very rare in children and mostly affects males over the age of 40. The diagnosis is mostly clinical. The goal standard for management is surgery. This is a case report of BLT in a Cameroonian child. *Case History:* A skin sample was received at the anatomy and pathology laboratory of the Centre Pasteur in Cameroon. It came from a 13 year old child with no prior history who initially presented with a large genitoscrotal tumour. In the light of these clinical facts that did not tie to a certain diagnosis, a histopathological analysis was carried out which revealed a Buschke-Löwenstein tumour. *Discussion:* This case history describes an original case of a clinically unsuspected BLT in a Cameroonian child aged 13-year-old, with no prior history. This case was diagnosed on histology and confirms the importance of histopathological analysis to this diagnosis which remains difficult for non-dermatologists. *Conclusion:* To our knowledge and according to the data at our disposal, this is the first time that BLT has been described in a child in Cameroon.

Keywords: Buschke-Löwenstein Tumour, Child, Cameroon, Histopathology, Case Report

1. Introduction

Buschke-Löwenstein tumour (BLT), also known as giant condyloma acuminata, is a rare entity classified under verrucous carcinomas [1]. Very rare in children, it classically affects males in the post-pubertal period and in sexual activity [2]. It is a sexually transmitted infection caused by Human Papilloma Virus (HPV) with the most common types (90%) being 6 and 11, with lesser involvement of phenotypes 16 and 18 [3]. The most common risk factors are related to

immunosuppressed states, including HIV infection [4, 5], pregnancy [6], smoking and alcohol. Other risk factors include poor hygiene, homosexuality and multiple sexual partners.

The diagnosis is essentially clinical but can be supplemented by confirmatory histopathology. Surgery is the goal standard for management of this disease with wide margin resection, this due to the possibility of recurrence and risk of malignant degeneration [7].

Here is a case report of BLT diagnosed in a child with no prior history.

2. Case History

2.1. Patient Information

A skin sample from a 13-year-old boy living in the city of Yaoundé was received at the anatomy and cytopathology laboratory of Centre Pasteur in Cameroon. No information on the medical or surgical history of this patient was mentioned.

2.2. Clinical Data

Earlier on, he had consulted in urology for a large, ulcerated scrotal mass without further details. Physical examination revealed a multinodular tumour located at the genitoscrotal region. It had a cauliflower-like budding appearance with marked areas of ulceration (Figure 1).

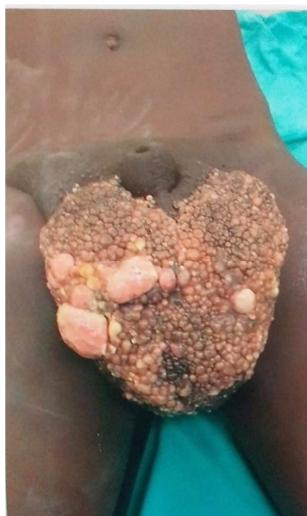

Figure 1. Large genitoscrotal tumor mass of cauliflower-like appearance.

2.3. Management

Surgical removal of the tumour was undertaken with sampling for histopathology analysis without mention of a probable or certain clinical diagnosis.

2.4. Diagnosis

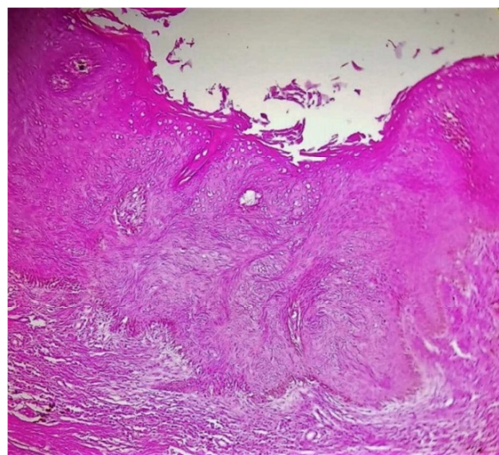


Figure 2. Hyperacanthosis and papillomatosis of the dermis; intracytoplasmic clear halot cells (HEx200).

Histopathological examination was performed. Analysis of the stained sample with haematein-eosin revealed an ulcerated, papillomatous, hyperacanthotic epidermis with koilocytes (Figure 2). In the dermis, there was dense fibrosis, infiltrated with lymphocytes and plasma cells (Figure 3).

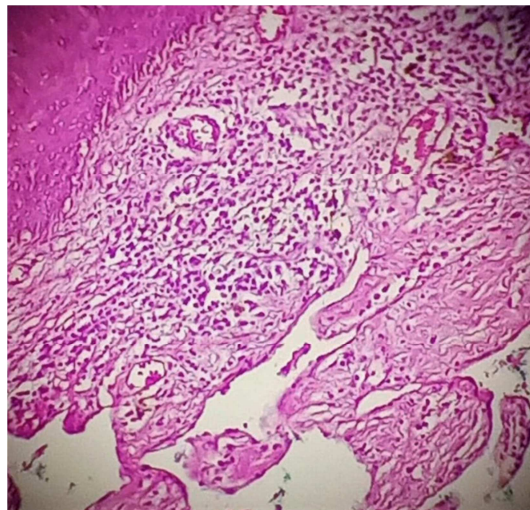


Figure 3. Dermal lymphoplasmocytic inflammatory infiltrate (HEx200).

All these histopathological findings coupled to the clinical iconography were strongly suggestive of a Buschke-Löwenstein tumour of genitoscrotal location in this young patient.

In addition, it should be noted that no other etiological examinations were marked on the examination form or undertaken by the clinician.

2.5. Informed Consent

We did not require informed consent in this case.

3. Discussion

BLT was first described in 1896, however, it was not until 1925 that Buschke and Löwenstein made it a separated entity [8]. Recently, coexistence of BLT and scrotal melanoma has been described [9]. Its prevalence in accordance with some studies is not far from 0.1% [10], a figure whose reliability remains to be demonstrated in the light of the many isolated cases that have been published and the resurgence of HIV. In our Cameroonian context, its prevalence remains unknown.

The disease is associated with risk factors such as HIV-related immunosuppression, multiple sexual partners and poor hygiene [11]. It is therefore usually transmitted sexually but can also be transmitted through water and soiled objects. BLT classically affects males in the post-pubertal period and at the height of sexual activity, between the 4th and 6th decades [11]. In our case report, this was a 13 years old patient, barely pubescent with no mentioned or recognized sexual activity. These facts contrasted with the literature review, leaving the most plausible hypothesis with regards to the etiology, while taking into account the absence of information on the HIV status, to be a lack of hygiene,

supported by the relatively young age of the patient. This also implied him living in the vicinity of a person infected with the Human Papilloma virus. However, given that the preferred route of transmission is sexual, the possibility of illtreatment or abuse should not be overlooked [2].

In accordance with our patient, BLT is preferentially located in the anogenital area [12-14], and was more specifically located in the penioscrotal area in the young boy. The literature review in children describes cases of BLT in both perianal and genital areas. The tumor does not appear to have an age-based site predilection.

The diagnosis of BLT is essentially clinical but can be supplemented by confirmatory histopathological examination in case of doubt [15]. Knowing that BLT can lead to cancer [7, 16] the histopathological examination ensures the elimination of a squamous cell carcinoma. It seems that in countries such as Cameroon, the clinical diagnosis of this pathology is still difficult for non-dermatologists. This might lead to delays in treatment, occurrence of possible unsightly and/or life-threatening complications.

Anatomopathology laboratory findings:

On gross examination, the mass received showed budding on its cutaneous side, giving it a cauliflower-like appearance with ulcerated areas and cysts of varying diameter with leaking fluid. This macroscopic description is in accordance with the literature, which says BLT is a tumor that realizes a voluminous cauliflower-like budding lesion sometimes ulcerated and/or fistulized to neighboring organs [17].

Similarly, microscopic examination revealed, as classically described, the presence of an epidermis showing images of acanthosis, papillomatosis and ulceration on numerous fields with the presence of koilocytes [17]. The whole, overhanging a fibrous dermis and seat of a chronic inflammatory infiltrate made of lymphocytes and plasmocytes. This reassures us that histopathology has a key role to play in the management of this disease, whether or not coupled with HPV typing tests.

The management of BLT consists of a surgical removal of the mass with wide margins to avoid recurrence [1, 18]. However, recent publications have rarely reported cases of spontaneous healing of TBL [19].

4. Conclusion

Although Buschke-Löwenstein tumor is a pathology of sexually active adults, it can occur in subjects of pediatric age without any prior history. We reported an original case of BLT both anamnestic (no known history/risk factors), epidemiologically (contamination of a child), and diagnostically with the contribution of histopathology to the diagnosis.

Conflicts of Interest

The authors declare no conflicts of interest.

Author Contributions

CRBMM: contributed mostly to the design of the manuscript and provided input on all drafts as well as the final version; EAK: contributed to the design and provided input on all drafts and the final version; RGE: contributed to the design and provided input on drafts and the final version; JCF and FGEM: Provided comments on drafts and final version as well as clinical iconography; PJAA: contributed to the design, coordination, and provided input on all drafts and final version.

All authors contributed to the conduct of this work. They all read and approved the final version of the manuscript.

References

- [1] Lévy A, Lebbe C. Prise en charge des tumeurs de Buschke-Löwenstein. *Ann Urol.* 2006 Jun; 40 (3): 175–8.
- [2] Schneider A, Lacreuse I, Devos M, Molinaro F, Moog R, Kauffmann I, et al. SFCP-P11 – Chirurgie viscérale – Tumeur anale de Buschke-Löwenstein chez l'enfant : 2 observations. *Arch Pédiatrie.* 2008 Jun; 15 (5): 906.
- [3] Nieves-Condoy JF, Acuña-Pinzón CL, Chavarria-Chavira JL, Hinojosa-Ugarte D, Zúñiga-Vázquez LA. Giant Condyloma Acuminata (Buschke-Löwenstein Tumor): Review of an Unusual Disease and Difficult to Manage. Perez-Lopez FR, editor. *Infect Dis Obstet Gynecol.* 2021 Jun 30; 2021: 1–5.
- [4] Ledouble V, Sclafani F, Hendlisz A, Gomez Galdon M, Liberale G. Buschke-Löwenstein tumor in a human immunodeficiency virus-positive patient: a case report and short literature review. *Acta Gastroenterol Belg.* 84 (2): 343–5.
- [5] Kowo M, Nzoume Nsope Mengang J-M, Simeni Njonnou SR, Kouotou EA, Atangana PJA, Ankouane Andoulo F. Giant anogenital tumor of Buschke-Löwenstein in a patient living with human immunodeficiency virus/acquired immunodeficiency syndrome: a case report. *J Med Case Rep.* 2022 Dec 18; 16 (1): 116.
- [6] Cui T, Huang J, Lv B, Yao Q. Giant condyloma acuminatum in pregnancy: A case report. *Dermatol Ther.* 2019; 32 (4): e12972.
- [7] Elsayed AG, Sola-Rufai ST, Griswold D, Pacioles T. Verrucous carcinoma arising in a long standing Buschke-Löwenstein tumor. *Clin case reports.* 2019 Apr; 7 (4): 836–8.
- [8] Kadouri Y, Nouini Y. Buschke-Löwenstein' tumor. *Pan Afr Med J.* 2020 Aug 28; 36: 359.
- [9] Chraïbi M, Harmouch T, Znati K, El Fatemi H, Chbani L, Bennis S, Armatati A, Ahallal A, Farih My H. Tumeur de Buschke-lowenstein associé à un mélanome scrotal. A propos d'un cas. *Progrès en urol.* 2012; 22: 70-72.
- [10] El Bessi M, Dougaz W, Jones M, Jerraya H, Dziri C. A Giant Anorectal Condyloma Is Not Synonym of Malignancy. *J Gastrointest Cancer.* 2019 Dec 6; 50 (4): 1026–8.
- [11] Purzycka-Bohdan D, Nowicki RJ, Herms F, Casanova J-L, Fouéré S, Béziat V. The Pathogenesis of Giant Condyloma Acuminatum (Buschke-Löwenstein Tumor): An Overview. *Int J Mol Sci.* 2022 Apr 20; 23 (9).

- [12] Ibrahimi A, Ziani I. Tumeur de Buschke-Lowenstein à localisation pénienne. *Pan Afr Med J.* 2020; 37. TŞ. Vulvar Verrucous Carcinoma and Genital Condylomatosis. *Curr Heal Sci J.* 47 (4): 602–7.
- [13] Zhang W, Wang Y, Chen W, Du J, Xiang L, Ye S, et al. Verrucous Carcinoma of the Vulva: A Case Report and Literature Review. *Am J Case Rep.* 2019 Apr 19; 20: 551–6. [17] Lemfadli Y, Samlani Z. La tumeur de Buschke-Löwenstein. *PAMJ Clin Med.* 2021; 7.
- [14] Ben Kridis W, Werda I, Charfi S, Toumi N, Boudawara T, Mzali R, et al. Buschke - Lowenstein anal tumor: an ambiguous entity. *Exp Oncol.* 2019; 41 (2): 182–4. [18] Akpadjan F, Adégbidi H, Attinsounon CA, Koudoukpo C, Dégbôé B, Agbessi N, et al. A case of reccuring giant condyloma of vulva in infant without sexual abuse successfully treated with electrocoagulation in Benin. *Pan Afr Med J.* 2017; 27: 159.
- [15] Sarr A, Thiam A, Sow O, Ondo CZ, Sine B, Ndiaye M, et al. Les tumeurs de Buschke-Löwenstein à propos de 8 cas. *PAMJ Clin Med.* 2020; 4. [19] Jin S, Liu L, Li R, Zhou X, Wang Z, Luan C, et al. A rare case of self-healing giant condyloma acuminatum. *Dermatol Ther.* 2022; 35 (1): e15189.
- [16] Vilcea AM, Stoica LE, Cernea N, Marinaş MC, Țenea-Cojan