

# Urinary Myiasis in a Girl Due to a *Telmatoscopus albipunctata* Larva: Case Report

Rosalinda Jimenez-Aguilar<sup>1,2</sup>, Ernesto Maravilla-Franco<sup>3</sup>, Dora Carranza-Salazar<sup>4</sup>,  
Javier Martinez Bautista<sup>5</sup>, Mauricio Cantellano Orozco<sup>2,6</sup>, Willebaldo Tenorio Gutierrez<sup>1</sup>

<sup>1</sup>Intensive Care Pediatric Unit, "Dr. Gaudencio González de la Garza, Centro Medico Nacional La Raza" Hospital, "Instituto Mexicano del Seguro Social" Institute, Mexico City, Mexico

<sup>2</sup>Pediatric Intensive Care Unit, Angeles Acoxpa Hospital, Mexico City, Mexico

<sup>3</sup>Clinical Microbiology Laboratory, Department of Infectious Diseases, "Instituto Nacional de Ciencias Médicas y Nutrición Salvador Zubirán" Institute, Mexico City, Mexico

<sup>4</sup>ProcliniQ Company, Clinic Research, Mexico City, Mexico

<sup>5</sup>Neurology, Angeles Acoxpa Hospital, Mexico City, Mexico

<sup>6</sup>Urology Clinic, Angeles Acoxpa Hospital, Mexico City, Mexico

## Email address:

drarosyjimenez@hotmail.com (Rosalinda Jimenez-Aguilar)

## To cite this article:

Rosalinda Jimenez-Aguilar, Ernesto Maravilla-Franco, Dora Carranza-Salazar, Javier Martinez Bautista, Mauricio Cantellano Orozco, Willebaldo Tenorio Gutierrez. Urinary Myiasis in a Girl Due to a *Telmatoscopus albipunctata* Larva: Case Report. *International Journal of Clinical Urology*. Vol. 6, No. 2, 2022, pp. 84-87. doi: 10.11648/j.ijcu.20220602.14

**Received:** August 26, 2022; **Accepted:** September 13, 2022; **Published:** September 27, 2022

**Abstract:** Myiasis are parasitic infestations of humans or animals by fly larvae that infest skin, necrotic tissues, and natural cavities. They can be associated with nosocomial infections and cases of nasopharyngeal, testicular, and urinary myiasis have been reported. We presented a clinical case of urinary bladder myiasis and figure out the mechanism that allow the disease. The female patient arrived at Pediatric Intensive Care Unit at epilepsy condition so we have to induct to barbituric coma. The proper lab studies were conducted based on clinic practice guide; however, no positive results were found. She stops to pee and we identified a vesical balloon, then we decided to change the urinary catheter and then a lot of fly larvae were thrown, then we made the analysis of the fly specie. We notified to the Epidemiology Unit due to the patient was 15 days before in a small river at Morelos State in Mexico in a visit from a boy scout group. We made the lab studies to the other visitors to identify root cause and found out this was the contagion. We provided epidemiology hygienic recommendations at home to family. Finally, the patient was healed using antiparasitic medicine. As far as we know, there are no report of this type of myiasis in our country.

**Keywords:** Myiasis, Bladder, Larvae, *Telmatoscopus Albipunctata*

## 1. Introduction

Myiasis are parasitic infestations in humans or animals by fly larvae that infest skin, necrotic tissues, and natural cavities [1-3]. This term was first used in 1840 by Hope, who proposed to the Royal Society of Entomology in London the term "myiasis" (from the Greek myia: fly) to denominate the infestation by larval states of several species of fly [4].

Myiasis occur in all parts of the world, but their prevalence is higher in tropical and subtropical areas,

particularly in temperate climates [5]. Their incidence is probably underestimated since the majority of cases occur in rural areas [6, 7]. This can be classified depending on the location of the larvae in the human organism and it is generally defined as cutaneous, cavitary, and/or intestinal [8].

In humans, various predisposition factors are required for infestation, including: previous injuries, such as wounds, recent surgical episodes, basal cell carcinomas, lipedema, poor hygiene, immunodeficiencies, close coexistence of humans with animals, malnutrition, defective personal habits, population habits, climate, and, in some cases, life cycles of

the *Telmatoscopus albipunctata* fly [9, 10].

Dipterans are divided into three suborders: *Nematocera* (hematophagous flies, virus vectors, protozoa, and helminths), *Brachycera* (may cause facultative myiasis), and *Cyclorrhapha* (includes groups that cause obligate and facultative myiasis [11, 12]. *Clogmia* (*Telmatoscopus*) *albipunctata* is a primitive *Nematocera* of the Psychodidae family, Psychodinae subfamily, of cosmopolitan distribution [13].

Although *Clogmia albipunctata* adults are of minor medical importance, they are only nuisances, they have been implicated in allergy to inhalants in cases in South Africa [14], and as a possible vector mechanism of bacterial pathogens associated with nosocomial Infections in infested German hospitals [15].

*Clogmia albipunctata* larvae have been reported as a cause of human nasopharyngeal myiasis [13-16], testicular miasis [17], and urinary myiasis [18].

Fly Taxonomy:

Animalia: Kingdom

Kingdom: Metazoa

Subkingdom: Eumetazoa

Rado: Coelomata

Series: Protostomy

Phylum: arthropoda

Subphylum: Hexapoda

class: insect

Subclass: Holometabola

Order: diptera (say, two, pteron: wing)

Suborder: nematocera, the work mentions this order. And the other two of myiasis.

Infraorder: Psychodomorpha

Superfamily: Psychodoidea

Family: psychodidae

Subfamily: Psychodinae

Genre: Chlogmia

Species: albipunctata

Described by Williston [19] 1893.

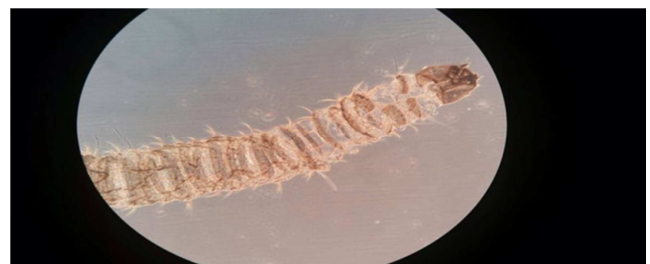## 2. Case Report

A 13-year old female, belonging to a group of explorers who 2 weeks prior to her current condition visited Tepoztlan, Mexico, where she swam in a river. Emergency admission due to somnolence of 4 days of evolution without eating; she was found incoherent, disoriented, with bradypsychia and bradylalia, with hallucinations and delirium. Admission to PICU (Pediatric Intensive Care Unit) with Glasgow of 14, increased osteotendinous reflexes, and bilateral positive Babinsky. Laboratory tests ruled out serious bacterial disease and CSF was compatible with viral encephalitis. PCRs for enterovirus, adenovirus, VHS-1VHS-2VHS-6 were negative; MRI reported extra-axial leptomenigeal reinforcement, a finding compatible with Meningitis; EEG was observed diffusely slow, without irritant activity. It was necessary to place a urinary catheter for monitoring in the PICU. After the support treatment, the neurological evolution improved, on

the second day the urinary catheter was removed, showing abundant larvae; a general examination of normal urine was performed showing macroscopically visible pupae. She was sent to the National Institute Salvador Zubirán where larvae were identified as *Clogmia* (*Telmatoscopus albipunctata*); Cystoscopy was performed in the operating room, visualizing two larvae; bladder cleaning was performed and biopsies were obtained from the base of the trigone where there were inflammatory changes characterized macroscopically as 1cm red colored maculae. The result of pathology without larva finding was reported with chronic inflammatory changes. An epidemiological screening was done to the family, turning negative; three cycles of Ivermectin treatment were given with an interval of 7 days. All the subjects of the group of explorers were checked without finding another case. The patient recovered completely.



**Figure 1.** We observe one of the *Telmatoscopus albipunctata* obtained during cystoscopy.



**Figure 2.** We observed a second larva of *Telmatoscopus albipunctata* obtained during cystoscopy.



**Figure 3.** *Telmatoscopus albipunctata* are observed.

## 3. Discussion

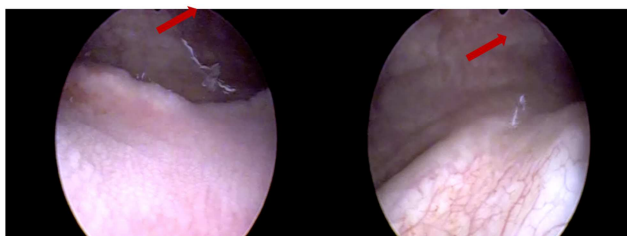
*Clogmia*, also called *Telmatoscopus albipunctata*, is a nematocera known as drainage or bathroom fly. Its distribution is rural and cosmopolitan, frequently living in places with stagnant water [18]. Infestations in the form of myiasis that affect the urinary tract are considered the rarest forms. Other than affecting organs or cavities, there are other

more frequent clinical forms, such as skin or infected wounds.

According to López Cepeda [20], from a clinical point of view, myiasis are divided into 1.- Cutaneous, 2.- Progressive, 3.- Wounds and 4.- Cavities and viscera. When affecting the bladder, its form of infestation is considered facultative or opportunistic; however, predisposing factors that condition its advance in the host have been described. Some of them are previous wounds, immunodeficiencies, close contact with animals, very poor hygienic habits, constant exposure to larvae in humid and hot places, and even some factors associated with the life cycle of the larva [18, 20].

Its clinical presentation is very varied and its symptoms are very unspecific; occasionally, urinary dysuria, urgent and frequent urination occur and they often depend on the number of larvae and the time of contact with the surface of the bladder. For its diagnosis, it is required to document the exit of larvae during urination or when placing a Foley catheter [21]. In our case, the exposure of our patient to the waters of a river in a subtropical zone of Mexico was the main predisposing factor. However, no urinary symptoms were reported prior to probe placement, obtaining adequate samples for analysis and identification. The decision to perform a diagnostic cystoscopy with biopsies allows to verify the absence of previous lesions in the urethra and bladder, in addition to obtaining bladder tissue to determine the degree of reaction with lymphocytes, neutrophils, eosinophils, giant cells, and plasma cells, as well as cross sections of larvae.

Treatment is based on oral ivermectin, 0.2 mg per kilogram, with good response in most cases and periodic cystoscopy controls at 3 and 6 months [22].



**Figure 4.** Cystoscopy image showing lesions caused by *Telmatoscopus albipunctata* (red arrow).

## 4. Conclusions

We know that there are multiple cases of myiasis in different organs described in international literature. In Mexico, there are few documented cases, with skin predominance, and those that affect the urogenital tract are limited to genital skin, such as scrotum. When occurring mainly in rural areas, its presentation is not usual and there are no characteristic data, only the documentation of the larva.

This case is probably the fourth reported worldwide for *Telmatoscopus albipunctata* involving the urinary tract, after what was reported in Egypt and Iran, as well as being the first case reported in our country. We recommend that due to

difficult and infrequent cases the larvae be properly documented and analyzed in institutions with experience in the identification of zoonoses.

## References

- [1] Mauricio González M, Greissy Comte M, Javiera Monárdez P, Marcelo Díaz de Valdés L., Iván Matamala C. Accidental genital myiasis by *Eristalis tenax*. Review Child Infect. 2009; 26 (3): 270-272.
- [2] Chan J C, Lee J S, Dai D L, Woo J. Unusual cases of human myiasis due to Old World Screwworm fly acquired indoors in Hong Kong. Trans R Soc Trop Med Hyg. 2005; 99: 914-918.
- [3] Makarov D, Bagga H, Gonzalgo M. Genitourinary myiasis (maggot infestation). Urology. 2006; 68 (4): 889.
- [4] Soler Cruz M. D. Myiasis studies at Spain over the last 100 years. Ars Pharmaceutica. 2000; 41 (1): 19-26.
- [5] Siddig A, Al Jowary S, Al Izzi M, Hopkins J, Hall MJ, Slingenbergh J. Seasonality of Old World screwworm myiasis in the Mesopotamia valley in Iraq. Med Vet Entomol. 2005; 19 (2): 140-150.
- [6] García Zapata M T, de Souza E S, Freitas F, Santos S. Human Pseudomyiasis generated by *Eristalis tenax* (Linnaeus) (Diptera: Syrphidae) en Goiás. J Braz Soc Trop Med. 2005; 38 (2): 185-187.
- [7] Sherman R A, Hall M J, Thomas S. Medicinal maggots: an ancient remedy for some contemporary afflictions. Rev Entomol 2000; 45: 55- 81.
- [8] Tarazona S, Sot, R. Myiasis incidence for patients on clinical review. Kasmera. 989; 17: 31-39.
- [9] Park P, Lodhia KR, Eden SV, Lewandrowski KU, McGillicuddy JE. Pin-site myiasis: a rare complication of halo orthosis. Spinal Cord. 2005; 43 (11): 684-686.
- [10] Kokcam I, Saki CE, A case of cutaneous myiasis caused by *Wohlfahrtia magnifica*. J Dermatol. 2005; 32 (6): 459-463.
- [11] Arosemena R, Booth S, Su D. Cutaneous myiasis. J Am Acad Dermatol. 1993; 28: 254-256.
- [12] Schiff T. Furuncular cutaneous myiasis caused by *Cuterebra* larva. J Am Acad Dermatol. 1993; 28: 261-3.
- [13] Nevill EM, Basson PA, Schoonraad JH, Swanepoel K. A case on myiasis nasal caused by *Telmatoscopus albipunctata* larvae (Williston) 1893 (Diptera: Psychodidae). S Afr Med J. 1969; 43: 512-4.
- [14] Mullen GR, Durden L. Medical and Veterinarian Entomology. Rutledge CL, Gupta KR, publisher. Chapter 11: The clothes moth fly and sandflies (Psychodidae). II edn. Cop San Diego, California: Elsevier Academic Press. 2009; pag. 147.
- [15] Faulde M, Spiesberger M. The *Clogmia Albipunctata* (Diptera: Psychodinae) fly as a mechanic agent for bacterial pathogens at the Germany Hospitals. J Hosp Infect. 2013; 83 (1): 51-60.
- [16] Mohammed N, Smith KG. Nasopharyngeal myiasis on humans caused by *Clogmia* (*Telmatoscopus*) *albipunctatus* larvae, Williston (Psychodidae, Dipt.). Trans R Soc Trop Med Hyg 1976; 70: 91.

- [17] Smith KG, Thomas V. The intestinal myiasis in humans caused by *Clogmia* (= *Telmatoscopus*) *albipunctata* larvae. Williston (Psy-Chodidae, Diptera). Trans R Soc Trop Med Hyg. 1979; 73: 349 -50.
- [18] Kamimura K, Arakawa RA. Report on Urinary myiasis caused by *Telmatoscopus albipunctata* moth fly. Med Vet Entomol. 1986; 37: 161-2.
- [19] <https://www.darwinfoundation.org/es/datazone/checklist?species=12207>
- [20] López Cepeda. Myiasis. Review Paper. Mexican Dermatology Journal 2006; 50: 94-104.
- [21] El-Badry et al: Urinary myiasis by *Clogmia albipunctata* larvae J Vector Borne Dis 51, September 2014, pp. 247–249.
- [22] Delgado Guerrero F, Reyes Vela C, Torres Aguilar J, Arellano

Cuadros R, Hernandez Leon O. Scrotal myiasis: Case report and bibliography review, Urology Mexican Academy Bulletin. 2015; 30: 41-42.

## Biography

### Rosalinda Jimenez-Aguilar

Pediatric Intensive Care Unit, “Dr. Gaudencio González de la Garza, Centro Medico Nacional La Raza” Hospital, “Instituto Mexicano del Seguro Social” Institute, Mexico City, Pediatric Intensive Care Unit at “Angeles Acoxa” Hospital, Mexico City. Current research on postoperative neurocritical care, neurocritical care, new-born and child cardiac surgery and immunology.

ORCID ID: Rosalinda Jiménez-Aguilar

<https://orcid.org/0000-0003-2104-2288>