

Paratesticular Embryonal Rhabdomyosarcoma (RMSE-PT): A Case Study in the Surgery Department of the Regional Hospital of Ziguinchor (Senegal)

Thierno Amadou Oury Sow^{1,*}, Samba Thiapato Faye², Mory Sangaré¹,
Mohamed Habiboullah Moustapha Ova², Ibrahima Diallo¹, Abdoulaye Sadjo Diallo³,
Alhassane Ismael Touré⁴, Cheikh Diouf¹

¹Surgery Department, Regional Hospital of Ziguinchor, Cheikh Anta Diop University of Dakar, Ziguinchor, Senegal

²Department of Urology-Andrology, Principal Hospital of Dakar, Cheikh Anta Diop University of Dakar, Dakar, Senegal

³Pathology Anatomy Department, Aristide Le Dantec Hospital, Cheikh Anta Diop University of Dakar, Dakar, Senegal

⁴Surgery Department, Regional Hospital of Fatick, Cheikh Anta Diop University of Dakar, Fatick, Senegal

Email address:

bobysowlo2015@gmail.com (T. A. O. Sow)

*Corresponding author

To cite this article:

Thierno Amadou Oury Sow, Samba Thiapato Faye, Mory Sangaré, Mohamed Habiboullah Moustapha Ova, Ibrahima Diallo, Abdoulaye Sadjo Diallo, Alhassane Ismael Touré, Cheikh Diouf. Paratesticular Embryonal Rhabdomyosarcoma (RMSE-PT): A Case Study in the Surgery Department of the Regional Hospital of Ziguinchor (Senegal). *International Journal of Clinical Urology*. Vol. 6, No. 1, 2022, pp. 63-65. doi: 10.11648/j.ijcu.20220601.24

Received: May 5, 2022; Accepted: May 24, 2022; Published: June 9, 2022

Abstract: *Introduction:* Paratesticular embryonal rhabdomyosarcoma (RMSE-PT) is a rare and aggressive malignant mesenchymal tumor developed at the expense of connective tissue, representing approximately 7% of all rhabdomyosarcomas. Embryonic and alveolar histological types are most common in children, the pleomorphic type occurs exclusively in adults, and the prognosis is poor. The treatment method consists of tumor resection surgery, radiotherapy, and/or adjuvant chemotherapy. Here, we report a case of paratesticular embryonal rhabdomyosarcoma in a 3-year-old child. Through this observation, we discuss the diagnostic and therapeutic. *Methods:* In this report, our patient was a 3-year-old child with a large, painless right purse that had evolved over four months and was gradually increasing in volume. Physical examination detected a right scrotal mass, hard, painless, necrotic, suggestive of gangrene, while the left testicle was palpated at the bottom of the bursa, of normal appearance. The diagnosis revealed scrotal gangrene. *Results:* During the surgery, a large inguinoscrotal tumor was realized, and the realization of a right orchidectomy by the scrotal way with complete excision and dissection of an inguinal lymph node was finally made. The tumor markers (beta-human chorionic gonadotropin and alpha-fetoprotein) were negative, except for lactate dehydrogenase (LDH), which was increased. The surgical specimen's immunohistochemistry revealed an embryonic rhabdomyosarcoma invading the spermatic cord. The ultrasound revealed a tumor mass in the right testis. Computed tomography performed one month after surgery was normal. *Conclusions:* The care is multidisciplinary, combining surgery, polychemotherapy, and radiotherapy. The rarity of the clinical and the delay in diagnosis were the aggravating factors in the prognosis of our patient.

Keywords: Rhabdomyosarcoma, Paratesticular, Surgery, Chemotherapy, Radiotherapy

1. Introduction

Paratesticular embryonal rhabdomyosarcoma (RMSE-PT) is a rare and aggressive malignant mesenchymal tumor that develops at the expense of connective tissue, representing

approximately 7% of all rhabdomyosarcomas [1, 2]. Embryonic and alveolar histological types are most common in children, with the pleomorphic type occurring exclusively in adults. The prognosis is poor [2, 3].

The treatment method consists of tumor resection surgery,

radiotherapy, and/or adjuvant chemotherapy [4]. Here, we report a case of paratesticular embryonal rhabdomyosarcoma in a 3-year-old child. Through this observation, we discuss the diagnostic and therapeutic implications.

2. Case Presentation

A 3-year-old child with no particular pathological history was referred from the emergency room for treatment of a large, painless right purse that had been evolving for about 4 months and was gradually increasing in volume. A clinical examination revealed an afebrile with a right scrotal mass that is hard, painless, necrotic, and reminiscent of gangrene; the left testicle is palpated at the bottom of the purse of normal appearance (Figure 1).

The emergency biological results were normal: Hb, TP, TCK, GS+FRH.

The postoperative tumor markers were: increased (FSH = 0.66 IU/ml; LDH = 566.7 IU/l; HCG less than 2; -fetoprotein = 2.01 IU/ml).

The diagnosis of scrotal gangrene was evoked and the indication of an emergency debridement posed after approaching the scrotal thinking that it is gangrene, surgical exploration found a voluminous inguinoscrotal tumor (Figure 2). The realization of a right orchidectomy by the scrotal way with complete exercise and courage of an inguinal ganglion was finally made (Figure 3). The operating suites were simple for a post-operative outing.

The tumor markers were apart from a slight increase in LDH. The anatomopathological examination with the immunohistochemical study of the operating room had concluded that a rhabdomyosarcoma invading the spermatic cord (Figure 3).

No margins and positive lymph nodes. The month operating suites were marked by a straight, budding hard, fixed, and painless scrotal mass (Figure 4).

Thoracic abdomen pelvic tomography (TDM, TAP) performed one month after surgery was normal.

After a multidisciplinary consultation meeting, the indication of a polychemotherapy was retained and the patient was sent to a reference center in medical oncology for the rest of the care.

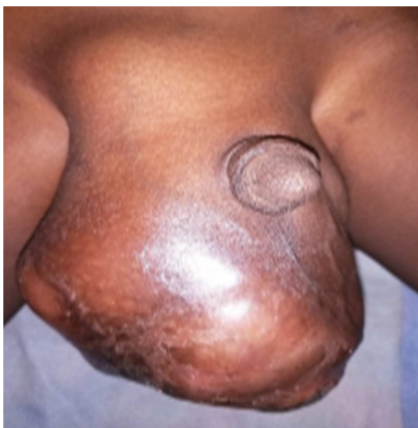

Figure 1. Necrotic and fluctuating right bursa.

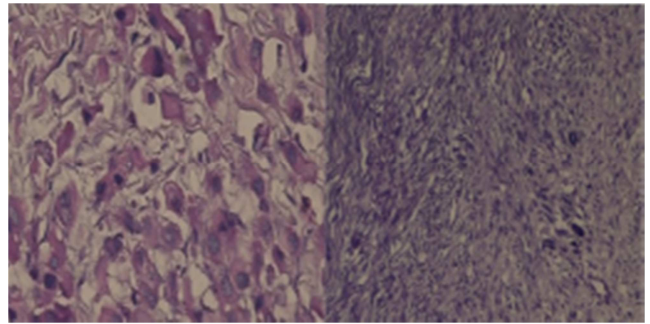


Figure 2. Histological aspects of embryonic paratesticular rhabdomyosarcoma, (Hematoxylin and eosin stain).

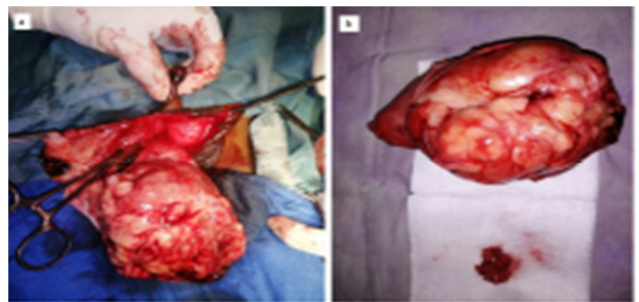


Figure 3. a. Cord clamped higher for orchidectomy, b. Operative specimen with lymph node dissection.

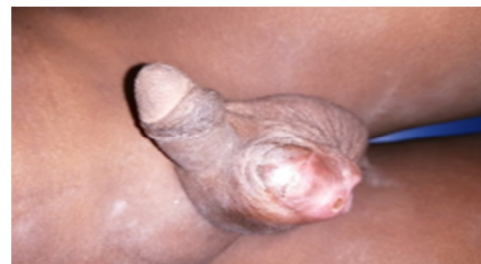

Figure 4. Local recurrence image.

3. Discussion

Paratesticular embryonal rhabdomyosarcoma (RMSE-PT) is a rare tumor. It accounts for 7% to 10% of all rhabdomyosarcomas of the genitourinary tract, followed by that of the prostate and bladder [5]. The age of onset is characterized by two peaks of incidence, the first between 2 and 5 years, and the second in adolescence [6]. The majority of these tumors are of the embryonic type (90%). The alveolar or pleomorphic subtypes are even rarer, with a darker prognosis [7]. In our patient, it occurred outside of these usual frequency peaks.

Sow O *et al.* [8] reported a case of paratesticular rhabdomyosarcoma in a young adult paratesticular rhabdomyosarcoma can develop from the spermatic cord, epididymis, and testicular coats, resulting in a painless scrotal mass [9]. Tazi *et al.* [10] reported in one study that the dosage of tumor markers is systematically indicated in the presence of a testicular mass, but these markers are normal in the case of rhabdomyosarcoma, and this was the case in one patient. In our patient, the tumor markers were normal.

Thoracic-abdominopelvic computed tomography makes it possible to search for invasion of the deep lymph node chains, especially lumbo-aortic and pelvic, and hepatic and pulmonary metastases [2]. In our case, the extension assessment made one month postoperatively was negative. However, the observed recurrence was probably due to incomplete resection of the tumor.

Macroscopically, it is a tumor whose origin is muscular, striated, grayish-white in appearance, firm, and encapsulated inconsistency.

The differential diagnosis can arise with the other paratesticular sarcomas: leiomyosarcoma, liposarcoma, and fibrosarcoma. There is no discriminating element between these different tumors in imaging. Their diagnosis of certainty can only be made in histology, after surgical excision of the tumor mass [11, 12].

Orchiectomy via the inguinal route with resection of the spermatic cord is the standard surgical treatment for localized forms [7]. The resection must be wide with safety margins. A scrotal approach is considered inadequate because of the risk of contamination of the skin by a microscopic or macroscopic residue and exposes the patient to the risk of local recurrence [13].

This approach is nevertheless used in 25% of cases, either in the context of clinical confusion with benign pathologies making this approach preferred, as in our patient, or in the context of a primary excision approach followed by or not of a hemicolectomy according to the appearance or not of a local recurrence. This approach is abandoned given the superiority of the multimodal protocol in terms of control of the initial disease [14, 15].

Our patient had a scrotal orchiectomy. After a one-month follow-up with a local recurrence, the staging assessment was unremarkable. We referred him to the oncology department for chemotherapy.

4. Conclusion

Paratesticular localization is the most frequent of the urogenital lesions. Several forms are described, and the embryonic variant is the most frequent. The care is multidisciplinary, combining surgery, polychemotherapy, and radiotherapy. The prognosis was bad. The rarity of the clinical picture and the delay in diagnosis was the aggravating factors of the prognosis of our patient.

References

- [1] Boris Amougou, Divine Eyongeta, Jean Paul et al. *Rhabdomyosarcome paratesticulaire: à propos d'un cas et revue de la littérature* [Paratesticular rhabdomyosarcoma: about a case and literature review]. PAMJ-39 (71). 26 May 2021.
- [2] El Mahdi Graioudi, Chakir Y, Gallou M, et al. *Rhabdomyosarcome paratesticulaire: à propos d'un cas* [Paratesticular rhabdomyosarcoma: about a case] The Pan African Medical Journal, 2019. 33.
- [3] Bognon Gilles, Akodjenou Joseph, Guédénon Medard, et al. *Paratesticular Rhabdomyosarcoma in 30 Months Old Child at the Lagoon Mother and Child Teaching Hospital (CHUMEL) in Cotonou*. Open Journal of Pediatrics, 2022, 12, 245-251 <https://www.scirp.org/journal/ojped>
- [4] Han kun Ng, Shankaran Thevarajah, Ann Feng Pan. *Paratesticular spindle cell rhabdomyosarcoma: A case report of a rare tumor*. *Pediatr Urol Case Rep* 2020; 7 (4): 107-111 <https://www.pediatricurologycasereports.com>
- [5] Ahsaini, M., Mellouki A, Ouattar K et al. *Un traumatisme scrotal négligé révélant un rhabdomyosarcome embryonnaire para-testiculaire: à propos d'un cas* [Neglected scrotal trauma revealing paratestic embryonic rhabdomyosarcoma: about a case]. The Pan African Medical Journal, 2018. 30.
- [6] Wu, H.-Y., H. M. Snyder III, and R. B. Womer, *Genitourinary rhabdomyosarcoma: which treatment, how much, and when?* *Journal of pediatric urology*, 2009. 5 (6): p. 501-506.
- [7] Sutow W, Sullivan MP, Ried HL, et al., *Prognosis in childhood rhabdomyosarcoma*. *Cancer*, 1970. 25 (6): p. 1384-1390.
- [8] Sow O, Sarr A, Ndiaye M et al., *Rhabdomyosarcome paratesticulaire: à propos d'un cas chez un adulte jeune* [Paratesticular rhabdomyosarcoma: about a case in a young adult]. PAMJ-Clinical Medicine, 2021. 5 (34).
- [9] Keskin, S., Moudouni S, Koutani A, et al. *Clinicopathological characteristics and treatment outcomes of adult patients with paratesticular rhabdomyosarcoma (PRMS): A 10-year single-center experience*. *Canadian Urological Association Journal*, 2012. 6 (1): p. 42.
- [10] Tazi, K, Moudouni S, Koutani A et al. *Rhabdomyosarcome paratesticulaire de l'adulte jeune* [Paratesticular rhabdomyosarcoma of young adults]. *Prog Urol*, 2000. 10 (3): p. 469-72.
- [11] Nesa, S, Lefebvre Y, Montfort J et al., *Rhabdomyosarcome paratesticulaire: à propos d'un cas* [Paratesticular rhabdomyosarcoma: about a case]. *Acta urologica belgica*, 1994. 62: p. 37.
- [12] Mhiri, M., Sellami F, Sellami M et al. *Les tumeurs malignes para-testiculaires: à propos de trois cas rares* [Paratestic malignant tumors: about three rare cases]. *La Semaine des hôpitaux de Paris*, 1989. 65 (43-44): p. 2652-2655.
- [13] Lopez Lopez C, Nova Sanchez E, Fernandez Puentes JC, et al. *Hydrocele as the first manifestation of paratesticular rhabdomyosarcoma*. *Archivos Espanoles de Urologia*, 1990. 43 (3): p. 288-291.
- [14] Dangle, P. P, Correa A, Tennyson L, et al. *Current management of paratesticular rhabdomyosarcoma*. in *Urologic Oncology: Seminars and Original Investigations*. 2016. Elsevier.
- [15] Seitz G, Dantonello TM, Kosztyla D, et al. *Impact of hemiscrotectomy on the outcome of patients with embryonal paratesticular rhabdomyosarcoma: results from the Cooperative Soft Tissue Sarcoma Group Studies CWS-86, 91, 96 and 2002P*. *The Journal of urology*, 2014. 192 (3): p. 902-907.