

# Vest-like Closure of Bulbospongiosus Muscle Flap During Augmented Anastomotic Urethroplasty

Susan MacDonald<sup>1,\*</sup>, Nathan Michalak<sup>2</sup>, Ross Decter<sup>1</sup>

<sup>1</sup>Department of Urology, Pennsylvania State University, College of Medicine, Hershey, USA

<sup>2</sup>College of Medicine, Pennsylvania State University, Hershey, USA

## Email address:

[smacdonald@pennstatehealth.psu.edu](mailto:smacdonald@pennstatehealth.psu.edu) (S. MacDonald)

\*Corresponding author

## To cite this article:

Susan MacDonald, Nathan Michalak, Ross Decter. Vest-like Closure of Bulbospongiosus Muscle Flap During Augmented Anastomotic Urethroplasty. *International Journal of Clinical Urology*. Vol. 6, No. 1, 2022, pp. 30-33. doi: 10.11648/j.ijcu.20220601.18

Received: November 10, 2021; Accepted: February 7, 2022; Published: February 25, 2022

**Abstract:** Introduction: Long urethral strictures with an obliterative segment remain a technical challenge when attempting a durable operative repair. An augmented anastomotic urethroplasty using buccal mucosa is typically performed in these cases, but the ideal position of the buccal graft is still under debate. Materials and Methods: A retrospective review was performed of a series of patients who underwent a novel technique of buccal graft placement during an augmented anastomotic urethroplasty. In these cases a ventrally placed buccal graft was quilted to a double layered vest-like closure of the bulbospongiosus muscle. Six cases in total were performed by a single surgeon at a tertiary academic center between 2008 and 2012 and outcomes were reviewed. IRB approval was attained for the study. Results: Mean stricture length was 7.3cm and median follow up was 2 years and 2 months with a range from 3 months to 12 years. Mean postoperative flow rates in short term follow up were 37ml/s and long term follow up 27.6ml/s. Three patients required no further intervention, two underwent dilation at 9 and 12 years postoperatively and one required redo urethroplasty. Conclusions: This new technique of using quilting a ventrally placed buccal graft to double layered bulbospongiosus muscle backing during anastomotic urethroplasty for long partially obliterative urethral strictures shows potential and warrants further study.

**Keywords:** Urethral Stricture, Augmented Anastomotic Urethroplasty, Ventral Onlay Buccal Graft, Bulbospongiosus Muscle Flap

## 1. Introduction

The surgical management of urethral stricture disease continues to evolve as new data is presented regarding novel techniques. End to end anastomotic urethroplasty is the optimal procedure for short strictures in the bulbar urethra with excellent long term success rates. [1-4] Lengthy urethral strictures prohibit excision and reanastomosis, requiring another approach, typically substitution urethroplasty with a graft. Oral mucosa, and particularly buccal mucosa, is an ideal graft material with minimal graft site morbidity and durable long-term outcomes. [3, 5-7] Advantages to buccal mucosa grafts (BMG) are attributed to wide availability, ease of harvesting, and favorable immunologic properties that are similar to urothelium. [2, 7-9]

Successful graft healing requires sufficient blood flow for

imbibition and survival. [7] Historically, pedicled skin flaps have been used in substitution urethroplasty due to their preserved vascular supply. Multiple studies have demonstrated lower success and higher complication rates for pedicled skin flaps compared to BMG urethroplasty, causing them to fall out of favor. [7, 10-13] In a randomized study comparing BMG to penile skin flaps, the BMG group trended towards better success rates and had significantly lower post-operative morbidity compared to the penile skin flap group. [9]

Despite the general success of oral mucosa, there is still debate over the best technique for graft placement. Due to limited long-term follow up periods and lack of prospective randomized controlled trials, this debate continues. [7, 9] Opposing views have been presented as to the best site for graft placement, ventral or dorsal, based on the healing process. [1, 2, 14] The first step in graft healing is imbibition

of nutrients, which requires adequate local blood supply to the tissue backing the graft. After several days, inosculation occurs, at which point capillaries penetrate the lamina propria. [7] As a superficial muscle of the perineum, the bulbospongiosus muscle is supplied by the perineal artery, a branch of the internal pudendal artery. We hypothesize that this well-vascularized tissue could reduce the time of graft ischemia and allow structural backing for the graft. For more complex strictures that are both lengthy and obliterative in a portion, we propose that a ventrally placed graft as part of an augmented anastomotic urethroplasty, using a double layered vest-like closure of the bulbospongiosus muscle as a graft bed provides excellent structural backing, blood supply for effective imbibition, and thus graft survival.

The purpose of this study is to examine the outcomes for a technical variation of ventral onlay augmented anastomotic buccal graft urethroplasty using the bulbospongiosus muscle as a backing to newly placed buccal grafts. We hypothesize that this novel approach provides vascular support for the healing graft and a durable repair, as well as fewer bothersome outcomes such as diverticula formation or post-void dribbling.

## 2. Materials and Methods

Institutional IRB approval was obtained for a retrospective review of patient charts who previously underwent a novel surgical technique to approach complex urethral stricture disease. We then identified six patients who were underwent a single-stage bulbar urethroplasty by stricture excision with placement of a ventrally positioned buccal mucosal graft in the bed of the double layered bulbospongiosus muscle closure. In each case the urethra was fully mobilized, transected and the area of maximal stricture excised. The dorsal wall with the urethral plate was reapproximated and a ventral buccal graft was placed using running locking 4-0 PDS suture. One side of the previously divided bulbospongiosus muscle was then fixed to contralateral edge of the corpora spongiosum where it was secured to the graft. The muscle was then quilted to the graft using interrupted 5-0 PDS sutures. The contralateral portion of the bulbospongiosus muscle was then brought across this to the opposite side and secured to the contralateral edge of the corpora spongiosum. Effectively the two sides of the bulbospongiosus muscle were folded over one another in a vest like fashion with the underlying portion quilted to the graft.

After approximately 3 weeks, a pericatheter urethrogram was performed. If no extravasation was seen, the catheter was removed and uroflowmetry was obtained at the next follow-up visit, approximately 1-2 weeks later. If extravasation was noted the catheter was retained an additional two weeks typically. Uroflowmetry was routinely carried out at approximately 4 months and yearly as indicated. The procedures were performed by a single surgeon at our institution from 2008 to 2012.

Medical records were reviewed to compile data regarding patient demographics, disease etiology, stricture length, procedure history, length of operation, post-operative flow

rates, post-operative interventions, erectile dysfunction and length of follow-up. Graft success was defined as not requiring post-operative interventions.

## 3. Results

A total of 6 patients with a mean age of 33 years (range 17 to 50) were included in the study. Etiology was idiopathic in 3 patients, trauma in 2 patients and suspected prior sexually transmitted disease (STD) infection in 1 patient. Mean stricture length was 7.3 cm (range 6.5-8cm). All six patients had undergone prior therapy. Three had undergone prior direct visualized internal urethrotomy, 2 had undergone dilation, and one a prior meatotomy. Mean operative time was 263 minutes (range 236 – 309 min).

Median length of follow up was 2 years and 2 months (range 3 month to 12 years). Uroflowmetry at 1 month follow-up was obtained in 6 patients, however, only four were available. One patient's maximum flow was not recorded, and one could not void during his initial follow up visit due to bladder shyness. The mean maximum flow of the remaining four cases was 37ml/s (range 29-51ml/s) with a mean voided volume of 402ml. Again, only four flow rates were available at the latest follow up, primarily due to the values not being scanned into the electronic record. Nonetheless, at the latest follow up, the mean maximum flow rate was 27.6 ml/s with a mean voided volume of 295ml.

Of the 6 cases, 3 (50%) required no further intervention, 2 (33%) underwent dilation of a focal stricture at one end of the repair 9 and 12 years subsequently, and one (16%) required redo urethroplasty 8 years later. The only complication noted in this group was a patient who required a pulmonary embolectomy and inferior vena cava (IVC) filter placement for a deep vein thrombosis (DVT) due to heparin induced thrombocytopenia in the early postoperative period.

## 4. Discussion

Buccal mucosa has many favorable properties for its use in substitution urethroplasty and has demonstrated good success rates. There has been debate regarding whether a graft should be placed ventrally or dorsally. In general, both approaches have similar outcomes although ventral urethroplasty is less technically challenging. [1, 2, 14] However, a common complication of ventral onlay grafts in the bulbar urethra involves sacculation or diverticulum type formation leading to post void dribbling. Approximately 15% of patients report this as bothersome symptom postoperatively. [9] In order for a graft to incorporate, an adequate vascular supply is required for imbibition and inosculation. Complications after substitution urethroplasty, including graft failure, may occur from poor blood supply to the newly placed graft. Fixation of the buccal graft to the highly vascularized bulbospongiosus muscle may provide a more efficient source of blood flow to the free graft, reducing the time of ischemia. [14] Furthermore, the technique of wrapping the muscle around the urethra provides mechanical support to the graft, which may then be

more resistant to sacculation.

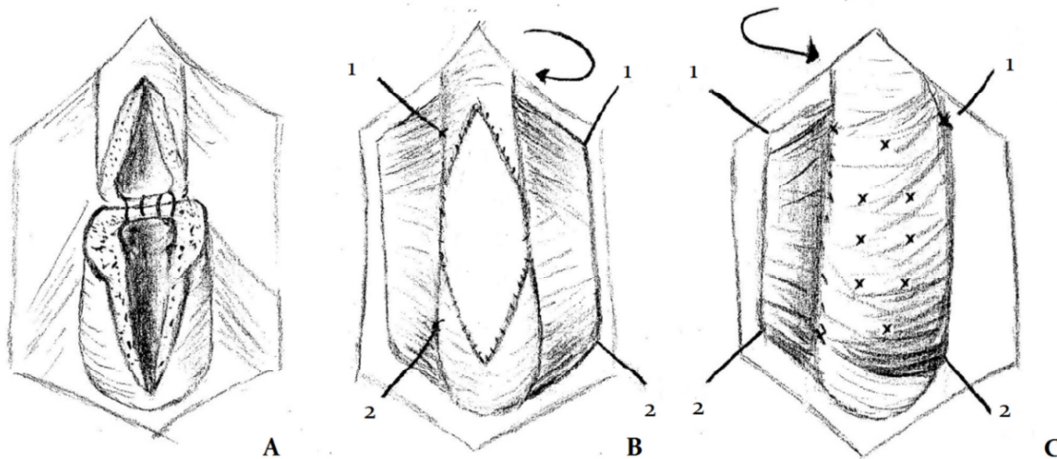
Another challenge in urethral reconstruction is that the variability of stricture etiology, length and diameter create heterogeneous patient groups and make randomized studies difficult. In our small series we have a cohort of patients with long segment bulbar urethral strictures (>6cm) containing an obliterative segment, which requires both anastomosis to remove the obliterative segment as well as a buccal graft to augment the longer, but decreased diameter area. We used a novel technique of ventral only buccal graft that was quilted to and backed with a vest-like double layered closure of the bulbospongiosus muscle to provide both blood supply and support to the extensive repair. We believe the 50% success rate, and additional duration of 9 and 12 years prior to requiring a minimal endoscopic intervention (dilation) are an indication that this technique may warrant further study given the severity of the disease process in this particular patient population. Those with available postoperative flow rates were excellent and only one patient suffered a complication, which could occur with any patient given heparin as DVT prophylaxis.

There are several limitations to the study. First, the small sample size and retrospective nature of the review is a

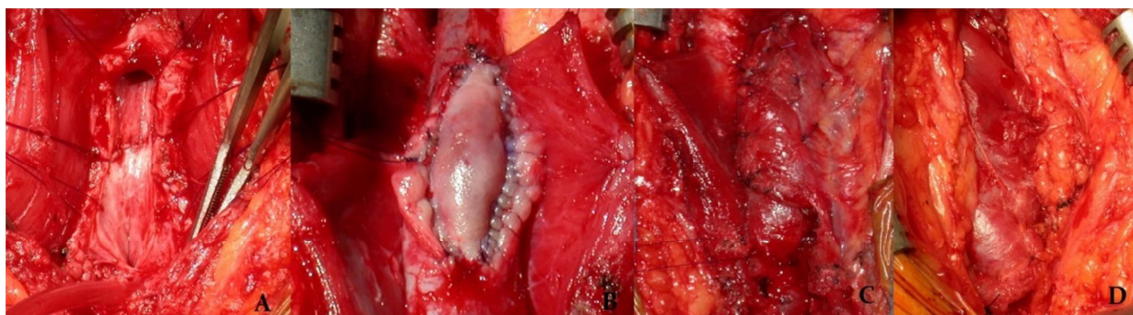
significant limitation. Also, as with many small series in urethroplasty techniques, our patient population is heterogeneous with regard to stricture etiology, patient demographics and comorbidities. The data was collected at a tertiary care institution and one patient had only short term follow up, which does not preclude outside intervention the authors are not aware of for either postoperative complications or further intervention for urethral stricture disease. Nonetheless, despite these limitations we believe the modification of a vest-like bulbospongiosus muscle closure as a backing to a buccal graft placed during an augmented anastomotic urethroplasty is promising and warrants further study.

## 5. Conclusions

For patients with long segment urethral strictures that are obliterative in a segment the failure and complication rates will necessarily be higher. We present a novel surgical technique involving quilting a ventral onlay buccal graft to a vest like closure of the bulbospongiosus muscle as a graft bed, which we believe warrants further investigation based on this initial small series of patients.



**Figure 1.** A. The obliterative portion of the stricture has been excised and the dorsal wall of the corpora spongiosum is anastomosed B. Ventral onlay graft sewn in place. The left lateral portion of the bulbospongiosus muscle will be rotated inward and sewn to the right edge of the corpora spongiosum C. The left lateral portion of the bulbospongiosus muscle has been quilted to the underlying graft and the right lateral portion will be rotated and sewn across this in a vest-like closure.



**Figure 2.** A. The obliterative portion of the stricture has been excised and the dorsal wall of the corpora spongiosum is anastomosed B. Ventral onlay buccal graft sewn into place with 4-0 PDS. C. The left lateral portion of the bulbospongiosus muscle has been sewn to the right edge of the corpora spongiosum and quilted to the underlying graft with interrupted 5-0 PDS sutures D. The right lateral portion of the bulbospongiosus muscle has been sutured to the contralateral edge in a vest-like closure.

## Funding

This research received no specific grant from any funding agency in the public, commercial, or not-for-profit sectors.

## Conflicts of Interest

All the authors do not have any possible conflicts of interest.

## References

- [1] Barbagli G, Guazzoni G, Lazzeri M. One-stage bulbar urethroplasty: retrospective analysis of the results in 375 patients. *Eur Urol* 2008; 53: 828-833.
- [2] Heinke T, Gerharz EW, Bonfig R, Riedmiller H. Ventral onlay urethroplasty using buccal mucosa for complex stricture repair. *Urology* 2003; 61: 1004-1007.
- [3] Markiewicz MR, Lukose MA, Margarone JE, 3rd et al. The oral mucosa graft: a systematic review. *J Urol* 2007; 178: 387-394.
- [4] Zinman L. Optimal management of the 3- to 6-centimeter anterior urethral stricture. *Curr Urol Rep* 2000; 1: 180-189.
- [5] Levy ME, Elliott SP. Graft Use in Bulbar Urethroplasty. *Urol Clin North Am*. 2017; 44 (1): 39-47.
- [6] Horiguchi A. Substitution urethroplasty using oral mucosa graft for male anterior urethral stricture disease: Current topics and reviews. *Int J Urol*. 2017; 24 (7): 493-503.
- [7] Wessells H, McAninch JW. Current controversies in anterior urethral stricture repair: free-graft versus pedicled skin-flap reconstruction. *World J Urol* 1998; 16: 175-180.
- [8] Filipas D, Fisch M, Fichtner J et al. The histology and immunohistochemistry of free buccal mucosa and full-skin grafts after exposure to urine. *BJU Int* 1999; 84: 108-111.
- [9] Soliman MG, Abo Farha M, El Abd AS et al. Dorsal onlay urethroplasty using buccal mucosa graft versus penile skin flap for management of long anterior urethral strictures: a prospective randomized study. *Scand J Urol* 2014; 48: 466-473.
- [10] Warner JN, Malkawi I, Dhradkeh M, Joshi PM, Kulkarni SB, Lazzeri M, Barbagli G, Mori R, Angermeier KW, Storme O, Campos R, Velarde L, Gomez RG, Han JS, Gonzalez CM, Martinho D, Sandul A, Martins FE, Santucci RA. A Multi-institutional Evaluation of the Management and Outcomes of Long-segment Urethral Strictures. *Urology*. 2015; 85 (6): 1483-7.
- [11] Mellon MJ, Bihle R. Ventral onlay buccal mucosa urethroplasty: a 10-year experience. *Int J Urol* 2014; 21: 190-193.
- [12] Barbagli G, Kulkarni SB, Fossati N, Larcher A, Sansalone S, Guazzoni G, Romano G, Pankaj JM, Dell'Acqua V, Lazzeri M. Long-term followup and deterioration rate of anterior substitution urethroplasty. *J Urol*. 2014; 192 (3): 808-13.
- [13] Rogers HS, McNicholas TA, Blandy JP. Long-term results of one-stage scrotal patch urethroplasty. *Br J Urol* 1992; 69: 621-628.
- [14] Fichtner J, Filipas D, Fisch M et al. Long-term outcome of ventral buccal mucosa onlay graft urethroplasty for urethral stricture repair. *Urology* 2004; 64: 648-650.