

## Case Report

# Peno-Scrotal Elephantiasis: An Observation and Literature Review

**Mohammed Mzyiene, Mustapha Ahsaini, Ziba Ouima Justin Dieudonne, Somuah Tenkorang, Mellas Soufiane, Jalal Eddine Elammari, Mohammed Fadl Tazi, Mohammed Jamal Elfassi, Moulay Hassan Farih**

Urology Division, Centre Hospitalier Universitaire Hassan II, University Sidi Mohamed Ben Abdellah, Fez, Morocco

### Email address:

[dr.mzyiene@gmail.com](mailto:dr.mzyiene@gmail.com) (M. Mzyiene), [ouimzib@gmail.com](mailto:ouimzib@gmail.com) (Z. O. J. Dieudonne)

### To cite this article:

Mohammed Mzyiene, Mustapha Ahsaini, Ziba Ouima Justin Dieudonne, Somuah Tenkorang, Mellas Soufiane, Jalal Eddine Elammari, Mohammed Fadl Tazi, Mohammed Jamal Elfassi, Moulay Hassan Farih. Peno-Scrotal Elephantiasis: An Observation and Literature Review. *International Journal of Clinical Urology*. Vol. 5, No. 1, 2021, pp. 21-24. doi: 10.11648/j.ijcu.20210501.15

**Received:** March 18, 2021; **Accepted:** April 1, 2021; **Published:** April 13, 2021

---

**Abstract:** Scrotal elephantiasis is a rare pathology Peno-scrotal elephantiasis (scrotal lymphedema) is most common in endemic filarian areas. Outside these areas this pathology remains quite rare. We report a case of primitive peno-scrotal elephantiasis. A 60-year-old patient with no significant pathological history, who had a significant increase of the bursa volume that had been evolving for years. The clinical examination found a bursary 46 cm in diameter with thickened skin and a penis buried in a glove finger. Exploration of the vascular axis of the lower limbs was normal. Peri-scrotal MRI noted significant infiltration of inflammatory-looking scrotal tunics, but found no obstructive cause. The patient was treated by a complete surgical resection of the pathological tissue and a peno-scrotal reconstruction. The evolution was marked by a progressive healing of the surgical wound, the patient was reviewed several times to assess the benefit of the treatment, he noted a satisfaction of the surgery allowing a good functional and aesthetic result. The aim of this case report is to present a specific management of a peno-scrotal elephantiasis in our hospital and to compare it with the review of literature on surgical management of this pathology. This condition is uncommon and challenging to manage for most urologists.

**Keywords:** Elephantiasis, lymphedema, Scrotum, Surgical Excision

---

## 1. Introduction

Scrotal or peno-scrotal elephantiasis (also called scrotal lymphedema) is a considerable increase more at least of the bursa volume with an unsightly appearance and psychological harm in the patients affected, the diagnosis is clinical.

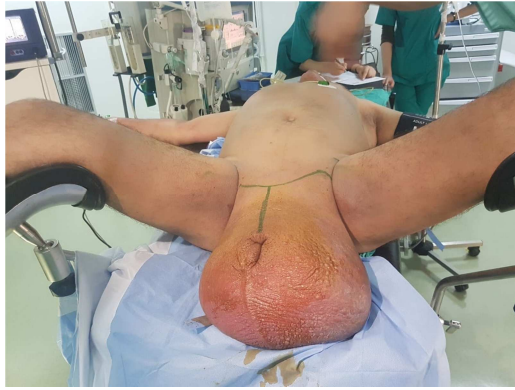It is a condition that affects sexual intercourses, professional and sporting activities and poses an aesthetic problem. The discovery of an elephantiasis that has been evolving for several years poses the problem of surgical treatment.

We report a case of idiopathic peno-scrotal elephantiasis which we present, through a review of the literature, epidemiology, clinical presentation, treatment and long-term outcome. Our goal is also to emphasize the behavior to be held in front of this rare pathology as well as to present the correct evolution on the clinical and aesthetic plane of our

patient taken care of within our service.

## 2. Case Report

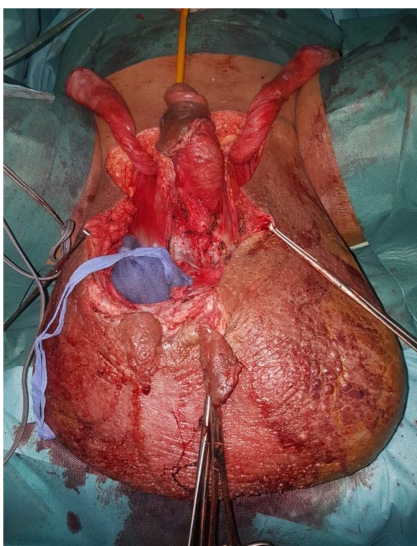
A 60-year-old patient with no significant pathological history, who had a significant increase of the bursa volume that had been evolving for years. The clinical examination found a bursary 46 cm in diameter with thickened skin and a penis buried in a glove finger. The lower limbs were the site of significant lymphedema (Figure 1). The search for microfilariae in the blood was negative, with no nephrotic syndrome. Exploration of the vascular axis of the lower limbs was normal. Peri-scrotal MRI noted significant infiltration of inflammatory-looking scrotal tunics, but found no obstructive cause.



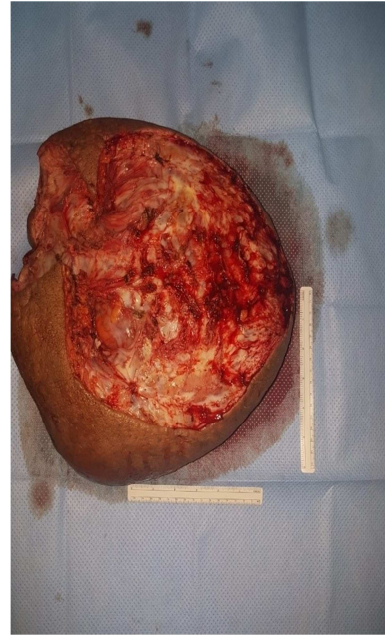**Figure 1.** Patient after his installation in the central operating room, after general anesthesia in gynaecological position, we observe a considerable increase in the volume of the bursa with an unsightly appearance making 40-50 cm in diameter with a thickened skin and a penis buried in a glove finger.

The patient was a candidate for surgical management of his pathology after informed consent on the surgical procedure, possible complications, and length of hospitalization.

The patient under general anesthesia on the operating table, in supine position. T-incision at the suprapubic level up to the sheath of the penis, unsheating and release of the bad penile skin with conservation of the healthy skin. Ligature and section of the cremaster. Circumferential incision respecting healthy scrotal skin. Surgical removal of a scrotal mass weighing 5kg was performed (Figure 2). A scrotal plaster covering the two testicles from two healthy lateral flaps and one posterior flap, the covering of the penis required a mesh skin graft (Figures 3). A urinary catheter of Foley CH16 was put in place for two weeks. A slight compressive bandage was made and left in place for 5 days to promote the success of the skin graft. The patient had received local care and antibiotics during his 10-day hospitalization.




**Figure 2.** This is a per-operative image, after placing a bladder probe, identifying the two cords and exposing the two Testicles.



**Figure 3.** This is the image of the operating room after the extirpability of the mass being 40-50 cm.

The anatomopathological result was in favour of scrotal lymphedema of inflammatory origin.

The evolution was marked by a progressive healing of the surgical wound, the patient was reviewed several times to assess the benefit of the treatment, he noted a satisfaction of the surgery on the aesthetic and functional level (Figure 4).



**Figure 4.** Final Outcome after cicatrization of surgery.

### 3. Discussion

Scrotal or penoscrotal elephantiasis or scrotal lymphedema is a more at least monstrous increase in the size of the bursa due to an abnormal collection of liquid rich in protein in the sub-tissue skin responsible for a less typical appearance

making diagnosis so easy by clinical inspection. The male predominance remains unexplained [1, 2]. It is observed especially in countries where the endemic of filariasis is widespread [3] and mainly affects humans from the age of 40 [4]. Scrotal elephantiasis is most often idiopathic, rarely congenital or secondary to other pathology. Congenital or idiopathic scrotal lymphedema falls within the scope of lymphangiomas which are known as dilatations of the lymphatic system, of dysplastic congenital origin, not regressive [5].

The scrotal lymphedema secondary to another etiology falls within lymphangiectasis acquired due to an obstruction of the lymphatic pathways which is due to an acquired condition of chronic mechanical or inflammatory origin such as surgical scar, abdominal or pelvic tumour, after pelvic carcinological surgery, after streptococcal infection, after radiotherapy, sequelae of chronic venous stasis or surgery of urogenital bilharziosis, Kaposi's disease, filariasis. Elephantiasis most often affects the scrotum or the peno-scrotal assembly, with isolated penile involvement being rare, but epididymoma-testicular content is almost always respected [6]. The diagnosis is clinical and remains too obvious before a large volume of the bursa with a parietal thickness doubled or tripled, so the scrotal skin becomes thick, cardboard, and loses its elasticity [7, 8]. Lymphatic edema can extend to the penis and bury it as a glove finger preventing sexual intercourse and sometimes causing urination problems [2, 9].

Doppler ultrasound removes an obstacle on the vascular axis of the two lower extremities. In case of filariasis, it shows adult worms moving within the lymphatic vessels. Ultrasound and abdominal computed tomography and even MRI can eliminate a compressive origin (pelvic or abdominal tumor) [10, 11].

Scrotal MRI allows tissue characterization to be well correlated with histology, mainly to specify the limits of surgical resection [12, 13]. The treatment is surgical, based on a broad removal of the pathological scrotal wall thus preventing recurrence.

Some conservative techniques to improve lymphatic drainage have been described such as lymphangioplasty by polyethylene or metal tubes, or lymphatico-venous anastomosis (Nielubowicz operation) between the arch of the long saphenous vein and the superficial inguinal lymphonodal group [5, 14, 15], but the permeability of anastomosis is temporary [6]. These techniques have been abandoned.

The surgical removal is followed by a scrotal plasty, several techniques have been described.

Two post-lateral scrotal flaps, often preserved, allow the reconstruction of a neo-scrotum. This technique used by many authors continues to give a good functional and aesthetic result [4, 9, 16].

Inguinal or suprapubic pedicular skin flaps [1, 6, 9].

Two fasciutaneous flaps of the thigh.

The use of thin free skin grafts [8, 9]. This method may induce spermatogenesis disorders by modifying local

testicular thermal regulation [2, 17, 18].

For penile skin grafting, thin free skin should be used which should be laid in a spiral fashion to avoid longitudinal or circular retraction on the penis [16, 19, 20].

The results of this surgery are excellent with a good functional and aesthetic result and little recurrence.

## 4. Conclusion

Scrotal elephantiasis is a rare pathology, the interest of which lies in its therapeutic management. The diagnosis is clinical and the radiological examinations allow to eliminate a secondary cause but should not delay in any case the treatment is always surgical, with a large pathological scrotal skin plaster and a scrotal plaster from two posterior-lateral scrotal flaps, allowing a good functional and aesthetic result.

The factors determining the choice of the surgical technique are: the type of elephantiasis (penile, scrotal, peno-scrotal), the preservation or not of the cranio-lateral and cranio-dorsal parts of the scrotum, the etiology (urethral narrowing, pelvic tumor, etc.), but also the surgeon's preferences.

## Conflicts of Interest

The authors do not declare any conflict of interest.

## Guarantor

M. Mzyiene and M. Ahsaini had full access to all the data in the study and took responsibility for the data integrity and accuracy of the data analysis.

## Acknowledgements

We would like to thank Professor AHSAINI for his assistance and guidance in this paper.

## Contributorship

Mzyenne Mohamed and Ziba Ouima Justin Dieudonne wrote the first draft of the manuscript.

All authors reviewed and edited the manuscript and approved the final version of the manuscript.

## Funding

This work was not supported by any funding.

## Ethical Approval

Ethical approval to report this case was obtained from CHU Hassan 2 ethics committee

CHU HASSAN 2

FEZ, MORROCO

UROLOGY DIVISION

contact@chu-fes.ma

## References

- [1] Apesos J, Anigian G. Reconstruction of Penile and Scrotal Lymphedema: *Ann Plast Surg*. 1991 Dec; 27 (6): 570–3.
- [2] Dandapat MC, Mohapatro SK, Patro SK. Elephantiasis of the penis and scrotum. A review of 350 cases. *Am J Surg*. 1985 May; 149 (5): 686–90.
- [3] Judge N, Kilic A. Elephantiasis Nostras Verrucosa. Excision with full-thickness skin grafting of the penis, scrotum, and perineal area. *J Dermatol Case Rep*. 2016 Nov 13; 10 (2): 32–4.
- [4] Khedroo LG. Reduction perineoplasty for scrotal elephantiasis: a method of surgical reconstruction of the penis and scrotum. *J Urol*. 1976 Nov; 116 (5): 679–80.
- [5] Ross JH, Kay R, Yetman RJ, Angermeier K. Primary lymphedema of the genitalia in children and adolescents. *J Urol*. 1998 Oct; 160 (4): 1485–9.
- [6] Masson E. Pathologie inflammatoire du scrotum [Internet]. EM-Consulte. [cited 2021 Feb 4]. Available from: <https://www.em-consulte.com/article/22760/pathologie-inflammatoire-du-scrotum>.
- [7] Fulmer LR, Fye C. Elephantiasis of the scrotum. *J Clin Ultrasound*. 1982 Mar; 10 (3): 143–4.
- [8] Wille S, Niesel T, Breul J, Hartung R. Elephantiasis of the legs with lichen sclerosus et atrophicus of the penis and scrotum. *J Urol*. 1997 Jun; 157 (6): 2262.
- [9] Ollapallil JJ, Watters DAK. Surgical management of elephantiasis of male genitalia. *Br J Urol*. 1995 Aug; 76 (2): 213–5.
- [10] Hussain O, Faris R, Weil GJ, Ramzy RM, El Setouhy M. Bancroftian filariasis in Egypt: visualization of adult worms and subclinical lymphatic pathology by scrotal ultrasound. *Am J Trop Med Hyg*. 1998 Dec 1; 59 (6): 864–7.
- [11] Liu J-C, Liu X-G, Xu C, Zhao H-F, Jiang X-Z. Scrotal elephantiasis associated with follicular occlusion triad: A case report and literature review. *Medicine (Baltimore)*. 2019 Apr; 98 (16): e15263.
- [12] Slama A, Jaidane M, Elleuch A, Ben Sorba N, Yacoubi MT, Mosbah AF. [Surgical treatment of penile-scrotal elephantiasis]. *Progres En Urol J Assoc Francaise Urol Soc Francaise Urol*. 2002 Apr; 12 (2): 337–9.
- [13] Kirakoya B, Zango B, Paré AK, Kaboré AF, Yaméogo C. Reconstructive surgery for giant penoscrotal elephantiasis: about one case. *Basic Clin Androl*. 2014; 24: 16.
- [14] Huang G-K, Hu R-Q, Liu Z-Z, Pan G-P. Microlymphaticovenous anastomosis for treating scrotal elephantiasis. *Microsurgery*. 1985; 6 (1): 36–9.
- [15] Huang GK. [Microsurgical therapy of scrotum elephantiasis]. *Z Urol Nephrol*. 1989 Sep; 82 (9): 459–62.
- [16] Konety BR, Cooper T, Flood HD, Futrell JW. Scrotal elephantiasis associated with hidradenitis suppurativa. *Plast Reconstr Surg*. 1996 May; 97 (6): 1243–5.
- [17] Moussa Y, Moussa M, Abou Chakra M. Penoscrotal Elephantiasis nostras verrucosa: A case report and literature review. *Int J Surg Case Rep*. 2019; 65: 127–30.
- [18] Hattori Y, Hayata N, Nakamura K, Takahashi T, Mitsumori K, Ohnishi H. Successful surgical resection and reconstruction of scrotal elephantiasis. *IJU Case Rep*. 2021 Mar; 4 (2): 79–81.
- [19] Holman CM, Arnold PG, Jurkiewicz MJ, Walton KN. Reconstruction of male external genitalia with elephantiasis. *Urology*. 1977 Dec; 10 (6): 576–8.
- [20] Raghavaiah NV. Reconstruction of Scrotal and Penile Skin in Elephantiasis. *J Urol*. 1977 Jul; 118 (1 Part 1): 128–128.