

## Case Report

# Migration of an Intra Uterine Device (IUD) on a Bilharzian Bladder: An Exceptional Fact About a Case

Mamadou Bissiriou Bah<sup>1,\*</sup>, Koutou Mahoï<sup>2</sup>, Ibrahima Bah<sup>1</sup>, Ricardo Lahoumbo Gnammi<sup>1</sup>, Mamadou II Barry<sup>1</sup>, Ibrahima Koussi Bah<sup>3</sup>, Demba Cissé<sup>1</sup>, Thierno Mamadou Oury Diallo<sup>1</sup>, Mamadou Diao Bah<sup>1</sup>, Daouda Kanté<sup>1</sup>, Abdoulaye Bobo Diallo<sup>1</sup>, Oumar Raphiou Bah<sup>1</sup>

<sup>1</sup>Department of Urology Ignace Deen National Hospital, Faculty of Health Sciences and Techniques, University of Conakry, Conakry, Guinea

<sup>2</sup>Regional Hospital Center of Kolda, Kolda, Senegal

<sup>3</sup>Department of Gynecology-obstetrics Ignace Deen National Hospital, Faculty of Health Sciences and Techniques, University of Conakry, Conakry, Guinea

### Email address:

drbahmamadou@yahoo.fr (M. B. Bah)

\*Corresponding author

### To cite this article:

Mamadou Bissiriou Bah, Koutou Mahoï, Ibrahima Bah, Ricardo Lahoumbo Gnammi, Mamadou II Barry, Ibrahima Koussi Bah, Demba Cissé, Thierno Mamadou Oury Diallo, Mamadou Diao Bah, Daouda Kanté, Abdoulaye Bobo Diallo, Oumar Raphiou Bah. Migration of an Intra Uterine Device (IUD) on a Bilharzian Bladder: An Exceptional Fact About a Case. *International Journal of Clinical Urology*. Vol. 4, No. 2, 2020, pp. 55-58. doi: 10.11648/j.ijcu.20200402.14

Received: June 22, 2020; Accepted: July 17, 2020; Published: July 23, 2020

**Abstract:** Intra uterine device (IUD) migration is a rare complication of female contraception. The mechanism for this migration is still poorly understood. Its association with a bilharzian bladder is exceptional. Urinary schistosomiasis is an endemic disease in our regions. A real public health problem, it affects poor populations of farmers and fishermen. And also women when they do their household chores in infested water. Through an observation, we analyze the clinical and therapeutic aspects of the intra vesical migration of an IUD on a bilharzian bladder. The diagnosis was made on a 31 years old patient who had an IUD 1 year 3 months ago. She had presented some urinary disorders such as dysuria, micturition burns and intermittent hematuria, evolving for 3 months. A urine pellet had highlighted *Schistosoma haematobium* eggs. After medical treatment and sterilization of the urine, the symptoms remained. A cystoscopy was performed which found the IUD in the bladder. There followed a surgical exploration by an under umbilical laparotomy for the removal of the IUD. Migration of the IUD into the bladder and bilharzian cystitis are two distinct nosologies affections but similar clinical manifestations. In both cases, a good clinical and paraclinical analysis makes it possible to make their diagnosis and ensure adequate management.

**Keywords:** Intra Uterine Device, Bilharzia Urinaria, Trans-uterine Migration

## 1. Introduction

The intrauterine contraceptive device is the most popular reversible and cost-effective contraceptive method [1]. Despite this, it is not free from complications; in particular its migration into the bladder. Compared to hemorrhages and infections, this complication is both rare and serious. According to the most recent studies, its rate is 1.3 to 1.8 per thousand [2].

However, its association with a bilharzian bladder is

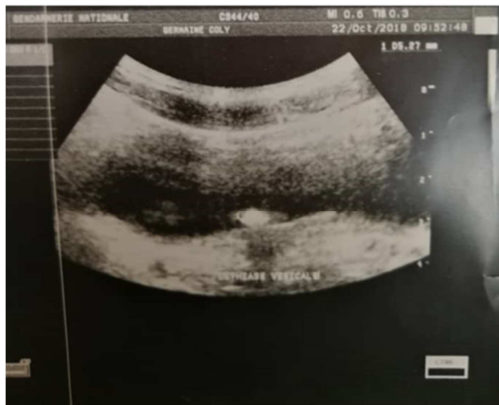exceptional. With a predominant urological tropism, *Schistosoma haematobium* is the causative agent of urinary schistosomiasis. This disease mainly affects populations in black Africa. More than 75% of women in most African countries in the south of the Sahara carry schistosomes in their urine [3, 4].

From this observation and a review of the literature we analyze the clinical and therapeutic aspects of intra vesical migration of an IUD revealed by urinary disorders on a bilharzian bladder.

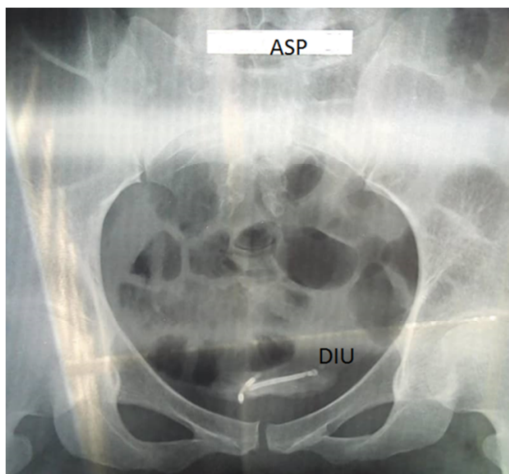
## 2. Observation

Ms. G. S, 31 years old with 2 gestures, two parities and two living children with no particular pathological history, had worn an intrauterine device 1 year 3 months ago. The patient reported a week after the insertion of the IUD a notion of disappearance of the IUD thread at the control. An requested ultrasound failed to locate the IUD. She had consulted in our department for intermittent hematuria, dysuria, and voiding burns evolving for 3 months. The clinical examination found a patient in good general condition with hypogastric tenderness. Upon vaginal examination, the uterus was normal in size with no abnormalities.

At the paraclinical level, the examination of the urine had revealed schistosoma haematobium bilharzia eggs. After a successful treatment of her bilharziasis, the patient returned three months later in consultation with a negative urine examination and persistence of urinary symptoms. This was how urinary ultrasound was requested, which concluded that there was 5.7 mm bladder stone without wall thickening or repercussions on the upper urinary tract (Figure 1). The image without preparation centered on the pelvis highlighted the metallic opacity in T of the IUD (Figure 2). At the cystoscopy under anesthesia we highlighted an intrauterine device in the shape of T adhering deeply to the posterior wall of the bladder.

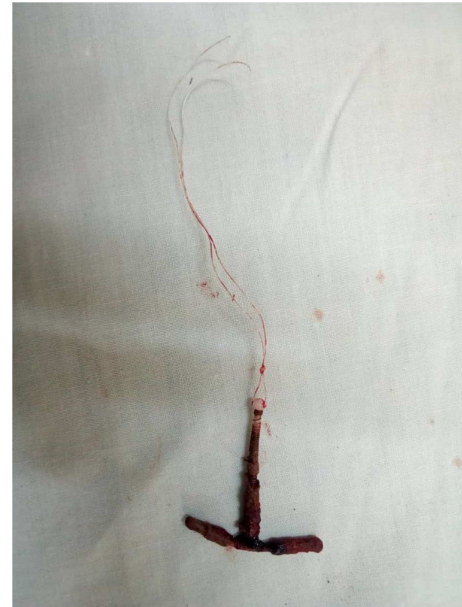


**Figure 1.** Ultrasound image of IUD evoking bladder stone.



**Figure 2.** T-shaped metallic opacity of IUD at ASP.

The diagnosis of migration of an intra vesical device was made. There followed a surgical exploration by laparotomy under umbilical for the removal of the IUD. The exploration identified a calcified IUD embedded in the posterior wall of the bladder with its extra vesical fillets. We have process to the removal of the IUD (Figure 3) and closed its route. The operating suites were simple.



**Figure 3.** IUD after surgical removal.

## 3. Discussion

Largely used in developing countries, the IUD is an interim contraceptive method, the most used in the world [5]. Despite all its advantages, the IUD after its pose can be exceptionally responsible for uterine perforation. Indeed, the injury of intraperitoneal hollow organ is a rare complication of the IUD contraceptive to such an extent that each reported case is often the subject of scientific publication. In the literature; Feghali J. et al. [6] had enumerated 160 cases of intra abdominal migration and less than 80 cases of intraveic migration, half of these cases complicated by the formation of bladder stone. The mechanism of this migration remains still poorly known to the extente that many theories have been advanced. For Hernandez-Valencia cited by Feghali J. [6] The IUD may be accidentally placed in intra-vesical through transurethral or by immediate uterine perforation, especially if it is set up by unexperienced paramedical staff. Many factors predispose to this migration, among other things, a embrittlement of myometer through multiple pregnancies and caesareans, an ante- or retro-shed uterus, hypoplastic and breastfeeding and probaly of an exaggerated uterine involution and the endometrial atrophy due to the hypoestrogenism induced by lactation, the pose of IUD too early after childbirth [7, 8]. The DIU migrates mainly in the peritoneal cavity (epiploon, wide lgament, retzius space), more rarely inside a viscera (ovarian, trumpe, rectum, sigmoid, appendix, bladder) as is the case in our patient or exceptionally intravascular (stenosis of the iliac

vein), sometimes in subcutaneous fat [9]. The complications of transutero-vesical migration are variable. They can be manifested by either pelvic actinomycose encompassing bladder, or a vesico-uterine fistula with catamenia hematuria, or the formation of a stone encompassing the IUD, representing the most common complication [10]. The intramyometrial migration begins with the incarceration of a branch of the IUD in the myometrium, inflammatory phenomena and the uterine contractions will allow the IUD to continue its migration. This inflammatory reaction causes a significant accumulation of enzymes and lysosomal lytic substances resulting from endometrial destruction and the secondary migration of the IUD under the action of uterine contractions. [11] Bilharziosis, meanwhile, causes significant bladder damages. The injury may be in the acute phase an atrophy of the transitional epithelium due to a significant deposit of bilharzie eggs in the lamina Propria with a subsequent reduction of blood supply at the level of the covering epithelium. The vessels contracts promotes the passage of eggs through the hyperhemic mucosa [12]. This phenomenon associated with an incarceration of one of the branches of the IUD in the myometrium to uterine inflammation as well as its contractions may be factors that have favored the migration of the IUD in the bladder of our patient. On the diagnostic level, the history of the disease and clinical signs are only of orientation elements as is the case of our patient. The patient who suffers from a bilharzian breach of the low urinary device always comes with the same set of symptoms: painful urination, pollakiurie, pyuria and hematuria [12]. These symptoms are identical to those found during the presence of a IUD in the bladder. The physical examination in the case of bladder bilharziosis gives little information apart from the discovery of a vesical tumor during the bi-manual examination. On the other hand, the migration is suspected in the absence of visualization of the IUD marker threads at the exocol. Rarely the IUD marker threads can be objectible through urethral meat during mutational efforts [8]. The Ultrasound/ASP pair allows the diagnosis of intravesical migration of the IUD in the majority of cases, however, it can wrongly give the diagnosis of bladder lithiasis as the case of our observation. Cystoscopy has made the diagnosis in our case. It remains the most reliable diagnostic means of intravesical migration of the IUD [13]. In urinary bilharziosis the images of cystoscopy are pathognomonic and different according to the evolutionary phase. This is the reference technique; It makes it possible to highlight specific bilharzian damages such as granuloma, the Bilharzian nodule, the sandy mat. In our patient, it is the examination of the urinary base which made it possible to determine diagnosis of bilharziosis three months before the evidence of the intravaginal migration of the IUD. This in front of the persistence of symptomatology despite a well-conducted antibilharzian treatment. The extraction of the IUD is usually done by endoscopic. For the case of our patient the therapeutic attitude had consisted to the extraction of the IUD surgically (cystotomy)

## 4. Conclusion

The intrauterine device is a simple and reversible method of contraception, which should be preceded by a thorough gynecological examination and followed by regular monitoring. However, its migration into the bladder is a rare complication. Its association with a bilharzian bladder of which they have the same symptomatology poses a problem of differential diagnosis. Urinary schistosomiasis mainly affects populations in black Africa.

In all cases, the interrogation and the paraclinical assessment (the couple ASP / Echo, cystoscopy, urinary pellet) make the diagnosis and allow an adequate treatment to be considered. This treatment is based on antibiotics for bilharziosis and IUD extraction, which can be done either endoscopically or by open surgery.

## Conflict of Interest Statement

The authors declare that they have no competing interests.

## References

- [1] Verim L, Akbaş A, Erdem MR. Intravesical Migration and Calcification of Intrauterine Device: A Case Report and Review of the Literature. *J Urol Surg* [Internet]. 5 déc 2015 [cité 1 juin 2020]; 2 (4): 197-9. Disponible sur: [http://cms.galenos.com.tr/Uploads/Article\\_11456/197-199.pdf](http://cms.galenos.com.tr/Uploads/Article_11456/197-199.pdf).
- [2] Arslan A, Kanat-Pektas M, Yesilyurt H, Bilge U. Colon penetration by a copper intrauterine device: a case report with literature review. *Arch Gynecol Obstet*. mars 2009; 279 (3): 395-7.
- [3] Gentilini M. Médecine tropicale. Médecine. Sciences Flammarion; 1993. 221-235 p.
- [4] Poggensee G, Feldmeier H, Krantz I. Schistosomiasis of the Female Genital Tract: Public Health Aspects. *Parasitol Today* [Internet]. 1 sept 1999 [cité 31 mai 2020]; 15 (9): 378-81. Disponible sur: <http://www.sciencedirect.com/science/article/pii/S0169475899014970>.
- [5] Thonneau P, Goulard H, Goyaux N. Risk factors for intrauterine device failure: a review. *Contraception* [Internet]. 1 juill 2001 [cité 1 juin 2020]; 64 (1): 33-7. Disponible sur: [https://www.contraceptionjournal.org/article/S0010-7824\(01\)00215-3/abstract](https://www.contraceptionjournal.org/article/S0010-7824(01)00215-3/abstract).
- [6] Feghali J, Bourgi A, Armache K. Migration intravésicale d'un dispositif intra-utérin Cas clinique et revue de la littérature. *J Med Liban*. déc 2016; 64 (4): 238-41.
- [7] Nohuz E, Battista R, Tamburro S, Leonenko M, Bayeh S, Varga J, et al. Un stérilet qui fait de plus en plus mal... où il ne suffit pas d'en voir les fils pour exclure une malposition! /data/revues/12979589/v42i4/S129795891100302X/ [Internet]. 10 avr 2014 [cité 1 juin 2020]; Disponible sur: <https://www.em-consulte.com/en/article/887231#N10108>.
- [8] Bacha K, Ben Amna M, Ben Hassine L, Ghaddab S, Ayed M. Dispositif intra-utérin migré dans la vessie. *Prog Urol*. 2001; (11): 1289-91.

- [9] El Kettani NE-C, Dafiri R, Imagerie de la migration des dispositifs intra-utérins. *Feuill Radiol.* 2007; 47 (3): 159–166.
- [10] Hasanain FH. The misplaced IUD. *Int J Gynecol Obstet* [Internet]. 2002 [cité 1 juin 2020]; 78 (3): 251-2. Disponible sur: <https://obgyn.onlinelibrary.wiley.com/doi/abs/10.1016/S0020-7292%2802%2900152-2>.
- [11] Deshmukh S, Ghanouni P, Jeffrey RB. Early sonographic diagnosis of intrauterine device migration to the adnexa. *J Clin Ultrasound JCU.* sept 2009; 37 (7): 414-6.
- [12] Koumare MAK, Soumare MS, Toure MAA, Ouattara MK, Dolo MA. prise en charge chirurgicale des sequelles de la bilharziose urinaire dans le service d'urologie du CHU DU Point «G» [Internet]. Université de Bamako; 2005 [cité 2 juin 2020]. Disponible sur: [www.keneya.net > fmpos > theses > med > pdf PDF](http://www.keneya.net/fmpos/theses/med/pdf/PDF).
- [13] Joual A, Querfani B, Taha A, EL Mejjad A, Frougui Y, Rabii R, et al. Intravesical migration of an intrauterine contraceptive device complicated by stones [Migration intravésicale d'un dispositif intra-utérin compliquée d'une lithiase]. 2004.